

BASIC SURGICAL TECHNIQUES

Textbook

Authors:

György Wéber MD, PhD, med. habil.
János Lantos MSc, PhD
Balázs Borsiczky MD, PhD
Andrea Ferencz MD, PhD
Gábor Jancsó MD, PhD
Sándor Ferencz MD
Szabolcs Horváth MD
Hossein Haddadzadeh Bahri MD
Ildikó Takács MD
Borbála Balatonyi MD

University of Pécs, Medical School

Department of Surgical Research and Techniques
20 Kodály Zoltán Street, H-7624 Pécs, Telephone: +36 72 535 820
Website: <http://soki.aok.pte.hu>

2008

PREFACE

The healing is impossible without entering into suffering people's feelings and to humble yourself in your profession. All these are completed by the ability to manage the immediate and critical situations dynamically and to analyze the diseases interdisciplinarily (e.g. diagnosis, differential diagnosis, appropriate decision among the alternative possibilities of treatment, etc.). A successful surgical intervention requires even more than this. It needs the perfect, aimful and economical coordination of operational movements. The refined technique of the handling and uniting the tissues –in the case of manual skills– is attainable by many practices, and the good surgeon works on the perfection of this technique in his daily operating activities.

The most important task in the medical education is to teach the problem-oriented thinking and the needed practical ability. The graduate medical student will notice in a short time that a medical practitioner principally needs the practical knowledge and manual skill in provision for the sick.

“The surgical techniques” is a popular subject. It is a subject in which the medical students -for the first time- will see the inside of the living and pulsating organism. They experience the success of the handling and suturing the tissues, as well as the control of the bleeding. They also will meet the miracles of the videoscopic technique for the first time. Although, “the surgical technique” was a beloved and interesting subject thus far, but our conviction is that the medical practitioner needs more than this. The time which was spent in the institute should be not only interesting but also useful. We must know that this is the only subject in the curriculum in the frame of which the student can practice the manual skill without endangering the patient. As the feedbacks certify, the students also feel the need for knowing and having this ability.

According to this need, we significantly reduced the number of the lectures while proportionally with it we increased the number of practices. “The new educational topics” is practice-oriented. In the practices the students will get acquainted with the basics of surgical techniques which are indispensable in the practitioner's work. They will practise these techniques systematically and at the end of the semester they will get a mark for this knowledge and the developed skill. The quality and the duration of the execution, and the number of the mistakes are objectively determined. So, at the end of the exam we can judge about the general manual ability of the candidates, or at least give them valuable informations which they can not obtain them anywhere else. Of course, the theoretical part of the exam gives a possibility that even the clumsy students pass the exam, but maximum with a satisfactory mark. We do believe that the gained knowledge and the exam which follows it, will unambiguously determine the manual ability of the student. What we consider more important than the concrete mark is the experience and the knowledge which the student gets in our institute. Because, these can decisively determine the way of the student's further professional development.

Pécs, 1 September, 2008.

György Wéber MD, PhD, med. habil.
Professor of surgery and head of the
Department of Surgical Research and Techniques

ASPECTS OF ANIMAL PROTECTION IN THE SURGICAL TRAINING

Department of Surgical Research and Techniques was founded in 1952 for the teaching of the basic surgical techniques and the improvement of the manual skills of the medical students, as well as the postgraduate physicians. The undergraduate education includes introducing medical students to “basic surgical techniques”, through both obligatory and credit courses that allows them to acquire the essential skills which could help them in their clinical rotations. Practices in the operating theater have been carried out for decades on anaesthetized animals exclusively. The students are subdivided into small working groups. This allows the effective teaching and the supervision of the student’s manual work.

The topic of our education has substantially been revisited in recent years. 1998/XXVIII Act of the Hungarian Parliament on Animal Protection and Consideration and Decree of Scientific Procedures of Animal Experiments (243/1998) had allowed the use of domesticated straying animals for human and veterinary research, as well as for education and experiments in universities. However, as an effect of the pressure applied by the animal protection organizations the use of straying dogs for research and education has been prohibited since 2004. Beside the above-mentioned reasons, the introduction of credit based education in medical training gave also the opportunity to rethink the education of surgical skills to the students, and so to renew the discipline. Ability to use one's hands efficiently in the performance of a specific task or operation needs multiple repetitions and practices of the same basic surgical techniques. With introducing of in vitro techniques the use of animals for education has been minimized. Because the control of bleedings is hard to be demonstrated on phantoms, therefore, “Tissue preparation, bleeding control and wound closure” have to be practiced on anaesthetized animals. Rats are used for this purpose, although the size of them is not really optimal for surgical practice.

The postgraduate training in our institute also includes the Ph.D. programs in a variety of topics for Hungarian as well as foreign graduates. In addition to this, advanced courses aimed at introducing residents and senior specialists to the most up-to-date surgical and therapeutical techniques are also available. These programs need the use of animals, mainly swine and rats. Regulation of animal experiments in Hungary follows the standard of the European Community. Licensing of procedures is controlled by The Committee on Animal Research of Pécs University according to the Ethical Codex of Animal Experiments. Our license entitled “Undergraduate and postgraduate teaching of surgical skills” is registered under the license code: BA02/2000-26/2006.

Pécs, 1 September, 2008.

János Lantos MSc, PhD

Associate professor

Chairman of the Committee on Animal Research (Pécs University)

| | |
|--|--------|
| 1. An introduction to the department and its curriculum | 5-6 |
| 2. History of surgery | 7-12 |
| 3. Layout and equipments of the operating room, technical background, sterilisation, disinfection, the possibilities to prevent the wound infection, asepsis, antisepsis | 13-19 |
| 4. Basic surgical instruments, suture materials, types of suture | 20-47 |
| 5. Wounds and the basic principles of wound management, haemorrhage and bleeding control, general and local consequences of injury | 48-63 |
| 6. Operation (acute, elective, patient preparation, surgical explorations) | 64-73 |
| 7. Basics of the laparoscopic surgery | 74-80 |
| 8. Basics of the microsurgery | 81-87 |
| 9. Description of practices | 88-110 |
| 10. References | 111 |

1. INTRODUCTION TO THE DEPARTMENT AND ITS CURRICULUM

Predecessors of the Departments of Surgical Research and Techniques were founded in 1952 as "Departments of Regional Anatomy and Surgical Techniques" in each medical universities. They primarily had the educational tasks. In Pécs, the teaching of regional anatomy took place in anatomic dissecting rooms, while the teaching of surgical techniques was performed on dogs. The role of the department in teaching the regional anatomy terminated in 1972, but since then the teaching of the practical aspects of the surgical techniques to the medical students are continuously going on. The department organizes the manual skill developing courses regularly, which are obligatory for the would-be specialists and it also provides further developing training courses for specialists. Beside the educational activities, the other main profile of the department is to perform researches connected to the pathophysiologic aspects of the surgical pathological pictures and the innovative surgical techniques which are built primarily on animal experimental models.

1.1. Education

Our aim is to introduce the hygienic and behavioural rules, as well as the basic surgical techniques, which attainment are indispensable to practice medicine. The department is also dealing with development of the manual skills of the students.

Lectures

1. An introduction to the department and its curriculum, history of surgery.
2. Layout and equipments of the operating room, technical background, sterilisation, disinfection, the possibilities to prevent the wound infection.
3. Basic surgical instruments, suture materials, types of suture.
4. Wounds and the basic principles of wound management, haemorrhage and bleeding control, general and local consequences of injury.
5. Operation (acute, elective, patient preparation, surgical explorations).
6. Basics of the laparoscopic surgery.

Practices

1. Operating room, the basic behavioral rules in the OR, surgical hand scrub, preparation of the surgical area (disinfecting, isolation).
2. Introduction to the basic surgical instruments, practicing their use.
3. Technique of knotting, the basic types of the knot.
4. Suture materials, types of suture, technique of suture removal.
5. To practice the basic types of the suture on pig foot.
6. To practice the basic types of the suture on pig foot
7. To practice the tissue preparation, wound uniting, and bleeding control on the anaesthetized animals.
8. To practice the management of the wound on the anaesthetized animals.
9. Introduction to the laparoscopic surgical tools, to practice the eye-hand coordination in the pelvitrainer.
10. To practice the laparoscopic movements in the pelvitrainer.
11. Practical exam, skill assessment.

Expectations from the students

This subject will be finished with practical and written examinations. The curriculum is presented in the lectures and practices and this note is a summary of them. The exam

questions and the auxiliary materials which are needed for an acquirement of the curriculum can be found on the website of the department (<http://soki.aok.pte.hu>). Taking part in practices is obligatory and the missed practice(s) must be substituted. The absentee should provide the office of the department with a certificate. The practices are built on each other that is reason the students must immediately substitute the missed one e.g. by taking part in the same practice in an another group -after receiving a permission to do so-. When there is an extraordinary indication, we will organize a replacement practice in the last week of the semester which date will be announced on the homepage of the department.

1.2. Our main research territories

I. Innovative surgical models

- **NOTES** (Natural Orifice Transluminal Endoscopic Surgery)
- **Hernia surgery** (silicone covered mesh, physiology and biomechanical investigations of abdominal wall etc.)
- **Wound closure techniques** (suture materials and other possibilities)
- **Vascular surgery** (stent grafts, laser welding, vascular staplers, osteointegration for femoral amputees)
- **Small bowel autotransplantation**
- **Acute haemarthrosis** (the role of the oxidative stress)

II. Pathomechanism of Oxygen Free Radicals (OFR)- mediated cellular injury

- To reduce the ischemia reperfusion injury of the myocardium (pharmacological possibilities, signal transduction pathways)
- Experimental and clinical examinations of the endogenous adaptation response mechanisms of the myocardium
- Examination of the oxidative stress, leukocytes and platelets activation in patients admitted to the ICU and in other clinical pictures
- Experimental and clinical examinations for reducing the degree of ischemia reperfusion injury of myocardium and lung injuries in patients undergoing cardiac surgery

Student Research Work related to the above-mentioned issues can also be found on the homepage of the department. For these students - besides the scientific researches- we also ensure possibilities to take part in operations, as well as to perform them (following getting appropriate experiences). We count on them in the education as well.

2. HISTORY OF SURGERY

"The history of surgery is the history of the last 100 years, which started in 1846 with the discovery of narcosis and the possibility of no-pain operation. Everything, which was before, is just a night of ignorance, pain and barren groping in the dark."

(Bertrand Gosset, 1956)

The history of surgery is divided into three periods:

I. Period

It lasted from the primaevial times until the middle of the 19th century, when only the removal of the injured parts had occurred.

II. Period

It lasted from the discovery of narcosis (1846) until the sixties (1960s). This period included not only the removal of the injured parts, but also their reconstruction. Milestone was the initiation and application of the principle of sepsis and antisepsis, discovery of blood-groups and the development of intensive therapy.

III. Period

It lasted from the sixties until nowadays. The development of the instruments, natural science researches (e.g. physiology, biochemistry, pharmacology, immunology, bacteriology, genetic, molecular biology), as well as the technical developments (e.g. diagnostic, computerization, technical arrangement of the wound, endoscopy, laparoscopy, invasive radiology) have betokened an enormous advance in the development and application of the new surgical approaches and interventions.

I. Period

Hippocrates (5th century B.C.) is the founder of the rational-empiric therapy. He treated the patients, taught the students and described his experiences in the island of Kos. In "Corpus Hippocraticum" we can read about the technique of bandaging, the treatment of fractures; dislocations; and emphysema thoracis, and even trepanation in details. The elements of asepsis (i.e. to keep clean and to change the bandage) appear in the management of the wounds.

In the middle ages, the ecclesiastical dogmas prevented the development of the medicine in Europe. At that time, the principle of healing was based on the will of God. Surgical interventions were performed by monks in monasteries. They performed the venesection, treated the cataract, and operated the haemorrhoids. Some army doctors -without having any special training -could also treat the patients at that period. It was often a big sacrifice from the side of the sufferer.

In 1543, they published the "De humani corporis fabrica" in Basel. It was written by Andreas Vesalius (1514-1564) who taught at the University of Padua. In his work, the Flemish -anatomist and surgeon who was born in Bruxelles- disproved more than 200 medical theories, which were accepted till that time. He approved the similarities and differences which exist in the set-up of the living organisms by means of experiments on animal models. The autopsies were big shows in every town and many times the local notabilities were present. These autopsies were usually performed by surgeons, who used their own instruments which were

used in the living persons later on. In this manner, they could also cause lethal infections plenty of times.

During the siege of Damvilliers in 1552, for the first time since the roman ages Ambroise Pare (1510–1590) used a vascular clamp. He also was the first who applied the ligatures to manage the bleedings.

II. Period: from the discovery of narcosis (1846) until the 1960s.

In 1772, a British scientists called as Joseph Priestley (1733-1804) discovered the laughing-gas (N₂O, nitrous oxide). In 1800, Humphry Davy (1778-1829), a British chemist, following his experiences determined that the nitrous oxide is suitable for surgical anaesthesia. Horace Wells (1815-1848), an American dentist, used nitrous oxide during a dental extraction in 1844.

On the 16th of October 1846 ("Ether day"), William Morton (1819-1868), an American dentist narcotized a patient in a Massachusetts General Hospital of Boston. The patient was under analgesia during a major surgical intervention. This was the first public demonstration of a surgical intervention in which the patient was narcotized by ether. Morton in cooperation with C. Jackson, who was a chemist, discovered the ether and first performed a self-experiment in Boston. He used a bulb which had two openings. In the inner one he put pieces of sponge which were impregnated in ether. The patient inhaled the gas and after an initial anxiety he falled asleep shortly after it. A neoplasm of the left jaw was removed by professor John Collins Warren in 5 minutes. After the patient became consciuos he declared that he did not feel any pain during the operation. This success opened a new era in treatment of surgical patients. In 1847, Oliver Holmes introduced the conception of "anaesthesia".

In 1847, Ignác Semmelweis (1818–1865), a Hungarian obstetrician, introduced the compulsory hand-washing with chlorinated lime to prevent the puerperal fever. It was obligatory for all doctors, medical students, as well as the nurse staff. Thereafter, the mortality rate of women, who were in labour, decreased from 30% to 1%. It unambiguously proved that decomposing organic matter on the specialists' hands, who made the examinations and treatments, propagated the mortal disease. In 1847, Kolletschka, who was a professor of forensic medicine, died in sepsis following an injury during an autopsy. Based on the report of autopsy of Kolletschka, Semmelweis determined that his septic clinical picture was similar to those seen in autopsies of women who died in puerperal fever. He recognized the common cause: The corpusles from the dead body could enter into the blood stream. Semmelweis had to face many rejections when he introduced the effectiveness of hand disinfectioning.

The Hungarian surgeon, János Balassa (1814-1868) was the first one in Hungary who applied ether narcosis. He was 28 years old when they nominated him as the head of the department of the Surgical Diseases. He was a professor of surgery, obstetrics and ophthalmology. He established and made internationally known the independent Hungarian Surgery by his multi-faceted surgical works and publications. He took part in the preparation of the universities educational reform and in the organization of modern surgical education. He worked out numerous operative procedures. He established the urological surgery. He performed a large number of urinary bladder incisions and the disintigration of the stones. He applied new methods in the field of the plastic (reconstructive) surgeries. His written works are of great importance in abdominal hernias and plastic surgeries. He set up the Medical Weekly Journal in 1857, which is the fifth one among the oldest medical journals all over the world and also a

part of the Hungarian Cultural Heritage. He was contemporary with the Pál Bugát (1793-1865), who created many (medical) words and so the main parts of those words which are used nowadays in the medical literature are originating from him.

1860. Louis Pasteur (1822–1895) worked out the “germ theory”. He also assumed that microscopic particles, which are originated from the surrounding tissues, cause wound infection and pus formation.

1861. Sándor Lumnitzer (1821-1892), a Hungarian surgeon, effectively dealt with the plastic surgery. He was an excellent traumathologist and introduced many technical innovations.

1867. Sir Joseph Lister (1827-1912), who was a professor of surgery in Glasgow, based on the “germ theory” of Louis Pasteur introduced the disinfecting processes in surgery. He believed that even in the case of a complicated fracture there is only a need to inject a material into the wound which can kill the septic germs. Lister found the carbolic acid (phenol) as an effective material for this purpose. In the operating theatre Lister sprayed carbolic acid onto the operative area, onto the instruments and bandages, and even onto the air. His “antiseptic theory” revolutionized the surgery, since the surgeons were incapable of managing the wound infection until that time. Hümér Hüttl (1868-1940) played an important role in the spread of the antiseptic surgery in Hungary.

1878. Emil Theodor Kocher (1841-1917), a Swiss surgeon, edited his book about the surgical removal of goitres. He paid more attention to the courses of the vessels than his ancestors. He avoided the injury to the recurrent laryngeal nerve. He also saved the neck muscles resulting to good cosmetic results. In 1909 he was awarded the Nobel Prize for his work on the thyroid gland.

1879. Jules Émile Péan (1830-1898), a French surgeon, resected the stomach partially due to a pyloric cancer and then sewed the remaining part to the duodenum.

1881. Theodor Billroth (1829-1894), an Austrian surgeon, performed the first successful gastrectomy. The patient survived the intervention. He carried out the first oesophageal resection and the first total laryngectomy. In his experiments, he developed the optimal methods for surgical treatment of the cancers of the bladder and intestines. He applied the statistical analysis in medicine.

1886. Gustav Adolf Neuber (1850-1932), a surgeon from Kiel, applied the aseptic treatment of wounds aimfully to prevent the infections.

1886. Ernst von Bergmann (1836-1907), a surgeon who introduced the gas sterilization of the instruments in his clinic in Berlin. This was a determinate step towards the aseptic system of work.

1889. Charles McBurney (1845-1913) was an American surgeon. His classic report on early operative interference in cases of appendicitis was presented before the New York Surgical Society in its scientific session. He described that in 99% of cases the symptoms of inflammation are originated from the right lower part of the abdomen (i.e. from the appendix). He determined the area of greatest abdominal pain which is the exact place of the typical muscle guarding (nowdays, known as McBurney’s point). Later, he set forth in another paper

the incision that he used in cases of appendicitis, now called McBurney's incision.

1895. Wilhelm Conrad Röntgen (1845-1923), who was a German physicist, discovered the X-ray which revolutionized the patient treatment. In 1901, he was awarded the Nobel Prize in Physics.

1896. William S. Halsted (1852-1922) was a surgeon at the Johns Hopkins Medical School, who developed the surgical rubber gloves. In 1890 he asked the Goodyear Rubber Company to manufacture thin surgical gloves for his chief scrub nurse (and his later wife) Caroline Hampton who was suffering of dermatitis due to use of disinfectants. Joseph C. Bloodgood (1867-1935), who was Halsted's student, initiated the routine use of surgical gloves in 1896. This method reduced the incidence of the dermatitis, as well as the number of the postoperative wound infections.

1900. Hunter initiated the use of surgical mask. During sterile intervention, all participants use paper or textile cap - which covers their whole hair- as well as surgical mask.

1901. Karl Landsteiner (1868-1943), an Austrian pathologist, who discovered the blood groups and described the ABO and Rh systems. He was awarded the Nobel Prize in 1930.

1902. Imre Ullmann (1861-1937) was born in Pécs. He studied and worked in Vienna from 1880. Then he visited Pasteur in Paris and made experiments there. At the Vienna Surgical Society he reported the first case of renal autotransplantation in which the kidney was placed in the neck of a dog. He did not use any vascular suture. He sewed the ureter onto the skin. The kidney was functioning for five days. Later, he stopped his researches in this field but his results stimulated Carrel.

1902. Alexis Carrel (1873-1944), a French surgeon, developed and published a technique for the end-to-end anastomosis of blood vessels. Thus, he created the surgical basis of the cardiovascular surgery and organ transplantation. He took sewing lessons in Lyon to develop his technique. In 1904, he joined the American physician Charles Guthrie in Chicago. They transplanted vessels, thyroid gland, parathyroid gland, ovary, testicle and heart. Carrel was awarded the Nobel Prize for Physiology and Medicine in 1912.

1902. Georg Kelling (1866-1945) the word "laparoscopy" was used by him which is a Greek word: *αραπαλ*, meaning soft tissue, and *κωσωωεπ* meaning inspection.

1904. Ferdinand Sauerbruch (1875-1951) was a surgeon in Berlin. His main professional field was the thoracic- and lung surgery, especially the surgeries of alterations due to tuberculosis. In the Congress of German Surgical Society he demonstrated the pressure equalizing process invented by him.

1907. Gyula Dollinger (1849-1937) was a surgeon, who founded the Hungarian Surgical Society.

1907. Hümér Hütl (1868-1940). According to the Hungarian surgical belief, Victor Fischer (an ingenious designer of surgical instruments) was the inventor of the first surgical stapler that was used by Hümér Hütl. In 1924 Aladár Petz (1889-1953) designed this device further. The Petz-stapler spreaded world-wide as a routine instrument and became the prototype for future GI staplers.

Conrad Ramstedt (1867-1963) was a surgeon from Munster. In 1912, Ramstedt described a new technique to save the life of the infants suffering from spastic hypertrophic pyloric stenosis.

1914. William T. Bovie developed an innovative method. His electrosurgical unit let the high frequency alternating current pass through the body allowing it to cut or coagulate (electrocautery).

1923. With the support of the Charite in Berlin, they opened the Institute of Medical Cinematography. They put a camera above the operating table which was electrically directed and could make films from operations. These medical films primarily demonstrated the operative techniques.

1931. Rudolf Nissen (1896-1981) was a German surgeon. He was the first who performed a pneumonectomy in a patient who was suffering from bronchiectasia. He also developed the method of fundoplication of the stomach.

1938. János Veres (1903-1979) was a pulmonologist in Kapuvár. In order to prevent injuries of the lung while getting through the thoracic wall, Veres used his own new, special, spring-loaded needle to create safely an artificial pneumothorax which was a technique for treatment of the tuberculosis at that time. The instrument (Veres-needle) is spreaded world-wide in creating pneumoperitonuem during laparoscopy.

1944. Alfred Blalock (1899-1964) was an American heart surgeon in Baltimore. In the Johns Hopkins Hospital, he performed the first successful operation on a cyanotic infant ("blue-baby"), who had a syndrome of tetralogy of Fallot.

1950. Richard H. Lawler (1896-1982) was an American surgeon in Chicago. He performed the first kidney allotransplantation. He used a cadaver's kidney without application of any immunosuppression. The transplanted kidney functioned well at the beginning, but they had to reoperate the patient 10 months later, when they found a shrunken and pale kidney graft.

1954. Joseph E. Murray (1919-) performed the world's first successful renal transplantation between the identical twins at the Peter Bent Brigham Hospital in Boston. He was awarded the Nobel Prize in 1990. His surgical technique is – with minor modifications – still used.

1958. Pope Pius XII (1876-1958) said that doctors could not define the death: "within the competence of the Church to define death". This produced an ambivalent opinion in the public: "You are dead when your doctor says you are". In 1966, the French Medical Academy for the first time used the irreversible injury to the brain as a factor to establish (determine) the death instead of the cardiac standstill.

III. Period: From the 1960s

1962. András Németh performed the first kidney transplantation in Szeged.

1967. Christiaan Neething Barnard (1922-2001) performed the world's first human heart transplant operation in Cape Town, South Africa. The donor heart came from a 24-year-old woman, who had been killed in a road accident. The recipient was the 54-year-old Louis

Washkansky. The operation took 3 hours. Washkansky survived the operation and lived for eighteen (18) days when he died due to a severe infection.

1985. Erich Mühe (1938-2005) performed the first laparoscopic cholecystectomy in Böblingen. That time, the German surgical society degraded the method as the "keyhole surgery".

1990. Kiss Tibor performed the first laparoscopic cholecystectomy in Hungary (Pécs).

1998. Friedrich-Wilhelm Mohr (1951-) using the Da Vinci surgical robot performed the first robotically assisted cardiac bypass in the Leipzig Heart Centre (Germany).

2001. In New York Jacques Marescaux used the Zeus robot to perform a laparoscopic cholecystectomy on a 68 year old woman in Strasbourg (France).

2004. They started to perform the NOTES (Natural Orifice Transluminal Endoscopic Surgery) interventions with the use of flexible endoscopes in animal models. The human use of the technique promises the reduction of postoperative pain (no pain surgery), the decrease in possibility for adhesion, and the elimination of postoperative abdominal hernias. It also leads to an incisionless or no scar surgery.

3. LAYOUT AND EQUIPMENTS OF THE OPERATING ROOM, TECHNICAL BACKGROUND, STERILIZATION, DISINFECTIONING, POSSIBILITIES TO PREVENT WOUND INFECTION: ASEPSIS AND ANTISEPSIS

3.1. Operating theatre

Operation

All such diagnostic or therapeutic interventions, in which we disrupt the body integrity or reconstruct the continuity of the tissues are called operations. Two types exist: bloodless operations (e.g. reducing a joint dislocation or treating a closed fracture) and bloody operations (e.g. abdominal or thoracic operations).

Layout and equipments of the operating room

We talk about two types of operating theatres: septic and aseptic ones. In the septic operating theatre the infected parts of the body are operated (e.g. infected purulent wounds or a gangaerogenous part). In the aseptic operating theatre the danger of bacterial infection does not usually exist (e.g. varicectomy).

There is no need to build the septic operating room in a separate area. These two (i.e. septic and aseptic operating rooms) can even have a common corridor. The essence of it is: always to prepare the surgical area for the patient in a way that we do not put him (or her) in a danger of infection. Before entering into the operating room, you should change your dresses in the dressing (or locker) room (of the operating complex) and wear the surgical cap and the face mask. Following this, you can enter into the surgical territory. The patients are brought into the operating theatre –with the help of a specifically used transporting chair or bed- after passing through a separate locker room (of the operating complex).

The operating theatre is a 50-70 m² room, which does not usually have any windows. It is adequately lighted and its walls are covered with tiles up to the ceiling. It is artificially ventilated and is air-conditioned. The operating complex must be architecturally separated from the wards and the intensive care unit. The operating complex consists of: locker rooms (dressing rooms), scrub-up area, preparing rooms, and operating theatres. The walls and floor of the operating room should have no gaps. They should be cleaned easily. The doors should work automatically. It is equipped with central and portable vacuum system, as well as pipes for gases. Main layout: operating lamp, operating table, Sonnenburg's table, supplementary instrument stand, kick bucket, suction apparatus, diathermy, microwave oven, anesthesia machine and other instruments required during anesthesia (Figure 1.).

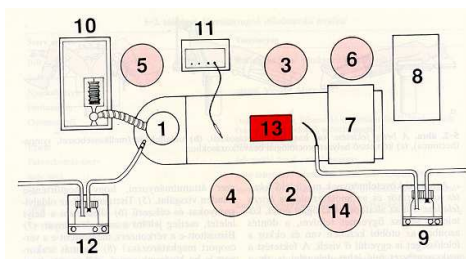


Figure 1. Equipments and positioning of surgical team: 1. operating table, 2. operator, 3. first assistant, 4. second assistant, 5. anesthesiologist and assistant, 6. scrub nurse, 7. Sonnenburg's table, 8. supplementary instrument stand, 9. suction apparatus, 10. anesthesia machine, 11. diathermy, 12. suction apparatus, 13. surgical territory, 14. waste bin

3.2. Rules in the operating theatre

1. Only those people whose presence is absolutely necessary should stay in the operating room.
2. Activity causing superfluous air flow (talking, laughing, and walking around) should be avoided.
3. Entry into the operating theatre is allowed only in operating room attire and shoes worn exclusively in the operating room. This complete change to the garments used in the operating theatre should also apply for the patient placed in the holding area (i.e. dressing room).
4. Leaving the operating area in surgical attire is forbidden.
5. The doors of the operating room must be closed.
6. Movement into the operating room out of the holding area is allowed only in a cap and mask covering the hair, mouth and nose.

General rules of asepsis concerning the personal attire

Taking part in an operation is permitted only after surgical hand washing and scrubbing. The scrubbing person must not wear jewels. Watches and rings should be removed. Fingers and nails should be clean. The nail should be short. Nail polish and artificial nail are forbidden.

Surgical team members in sterile attire should keep well within the sterile area; the sterile area is limited by isolation. Scrubbed team members should always face each other, and never show their backs to each other. They should face the sterile field at all times. Non-scrubbed personnel should not come close to the sterile field or the scrubbed sterile person, they should not reach over sterile surfaces, and they should handle only non-sterile instruments.

Behaviours and movements in the sterile operating room

The personnel is always keeping in mind the rules of asepsis while moving: they face each other and the sterile territory (e.g. operating table) while turning. They move in a way that their backs are facing the non-sterile surfaces. Always "the thorax is facing the thorax" and "the back is facing the back"! Hands must be kept within the sterile boundary of the gown. Sterile hands must not touch the cap, the mask or the nonsterile parts of the gown. Even spectacles must not be touched. You must not stretch out your hand to attempt to catch falling instruments and you are not allowed to pick them up. Do not take any instrument from the instrument stand; ask the scrub nurse to give it to you.

General rules of the aseptic operating room

Only sterile instruments can be used to perform a sterile operation. Sterile personnel can handle only sterile equipment. The sterile instrument will stay so if only the sterile person touch it (or if it comes in contact with only a sterile object). Instruments are located below the waist is not considered sterile. If a sterile instrument comes in contact with an instrument of doubtful sterility, it will lose its sterility. The edges of boxes and pots can not be considered sterile. A surgical area can never be considered sterile. However, the applications of aseptic rules of operations are mandatory!

3.3. Asepsis, antisepsis

Asepsis

Includes all those procedures, activities and behaviours designed to keep away the micro-organisms (bacteria, fungi, viruses) from patient's body and the surgical wound. In other words, the purpose of asepsis is to prevent the contamination. In a wider sense, the asepsis means such an

ideal state when the instruments, the skin, and the surgical territory do not contain microorganisms.

Antisepsis

Includes all those procedures and techniques designed to eliminate contamination (bacterial, viral, fungal) present on objects and skin by means of sterilization and disinfection. Because skin surfaces and so the operating field and the surgeon's hands can not be considered sterile, in these cases we can not talk about the superficial sterilization. In a wider sense, antisepsis includes all those prophylactic procedures designed to ensure surgical asepsis.

3.4. Prevention of the wound contamination

Before the operation

1. A careful scrub and preparation of the operative site (cleansing and removal of hair) is necessary.
2. Knowledge and control of risk factors (e.g. normalization of the serum glucose level in cases of diabetes mellitus, etc.).
3. In septic and high-risk patients, there is a need for perioperative antibiotic prophylaxis.

During the operation

1. Appropriate surgical techniques must be applied
2. Change of gloves and rescrub if necessary.
3. Normal body temperature must be maintained. Narcosis may worsen the thermoregulation. Hypothermia and general anesthesia both induce vasodilatation, and thus the core temperature will decrease.
4. The oxygen tension must be maintained at a proper level.

After the operation

1. Wound infection generally evolves shortly (within 2 hours) after contamination.
2. Hand washing is mandatory and the use of sterile gloves is compulsory while handling wound dressings and changing bandages during the postoperative period.

3.5. Sterilization, disinfection

Sterilization

This involves the removal of viable microorganisms (including latent and resting forms such as spores) which can be achieved by different physical and chemical means and methods. Important methods which are used frequently: autoclaves, gas sterilization by ethylene oxide, cold sterilization, and irradiation. Instruments and materials used during operations are sterilized.

Disinfection

This is the reduction of the number of viable microorganisms by destroying or inactivating them. Generally used methods: low-temperature steam, and chemical disinfectants (e.g., phenolics, chloride derivatives, alcohols, and quaternary ammonium compounds). Surgical hand scrub and surgical area disinfecting are considered as disinfecting procedures.

3.6. Scrubbing

Changing the clothes

Entry into the operating theater is allowed only in operating room attire and shoes worn exclusively in the operating room.

Surgical cap, face mask

The surgical team members should wear surgical caps and face masks before entry into the operating room. The cap should cover the hair completely. The mask should be tied securely.

Scrubbing, surgical hand disinfection

Surgical hand scrub should be done before any operation and sterile intervention. Hands can not be made sterile. The aim of the scrub is to reduce the number of transient and resident bacteria. The scrub eliminates the transient flora of the skin and blocks the activity of most resident germs located in the deeper layers. Nowadays, the scrubbing is carried out as in the Ahlfeld-Fürbinger 2-phase scrub. It consists of a mechanical cleansing followed by rubbing with a hand disinfectant.

Mechanical cleaning is the first phase of scrubbing. Wash the hands and forearms (up to elbow) thoroughly with the soap and warm tap water. The first phase should last till that time when we are satisfied of a thorough and careful washing (it does not have a time limit). After this, use a tissue paper to make your hands and forearms dry (Figure 2.).

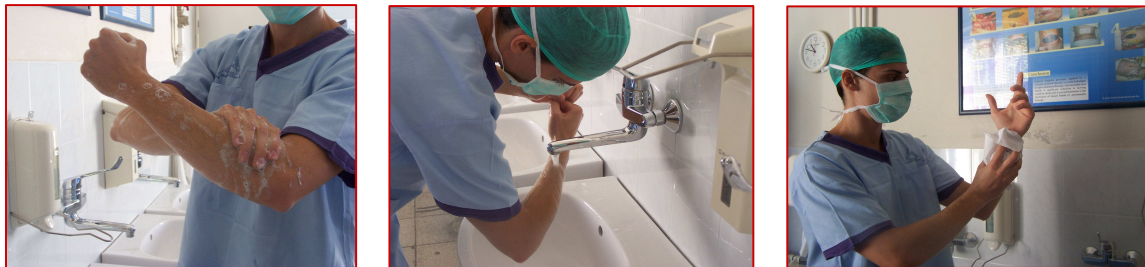

Figure 2. The first phase of the surgical hand scrub

The second phase is hand disinfecting. Rub with a disinfectant hand scrub agent for 5×1 minutes. The disinfected area should extend to the elbow. The unwashed skin should not be touched with the clean hands. This process should be repeated four times more, but the affected area will be smaller and smaller. The second time, the dividing line is at $2/3$ of the forearm; the third time, it is on the middle of the forearm; and the fourth time only $1/3$ of the forearm is involved. With the fifth dose we rub only the wrists and hands (Figure 3.).

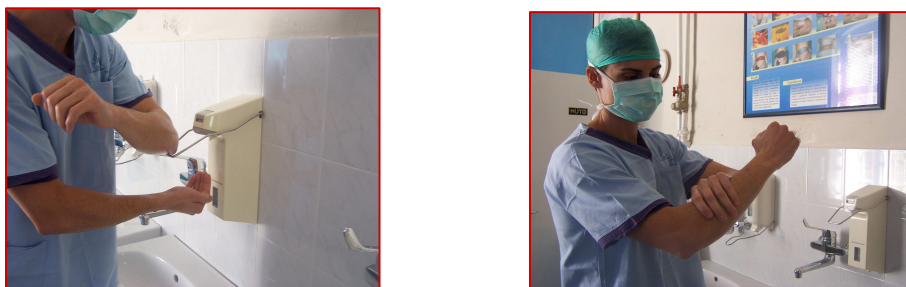


Figure 3. The second phase of the surgical hand scrub

The assistant -after scrubbing- enters the operating room and does the disinfection of the surgical territory. The surgeon enters the surgical suite immediately after the scrub. The hands are held above the elbows, in front of the chest to avoid touch any non-sterile object. After scrubbing, there is a need for an immediate gowning.

The gowning procedure

1. Lift the gown while you are grasping its middle part. Catch its neck piece. While keeping it away from your body, allow it to unfold.
2. Find the neck line and while holding the gown at this area unfolds it in a way that it's inner part is facing you. Turn the armholes towards yourself.
3. While holding the neck parts of the gown throws it up in air just a little and with a defined movement insert both arms into the armholes.
4. The assistant/scrub nurse stands at the back and grasps the inner surface of the gown at each shoulder. The gown is pulled over the shoulders and the sleeves up over the wrist. Meanwhile the cuffs of the gown can be adjusted. If there is a band, use it to fix the cuff. The assistant ties the bands at the back of the gown. Then, with your right hand catch the sterile right band located at the waist region of the gown and while crossing your (right) arm give this band to the assistant who grasps it without touching the gown and tie it at the back. It is important to know that these parts of the gown which are touched by the non-sterile assistant will lose their sterility and should not be touched by you (Figure 4.).

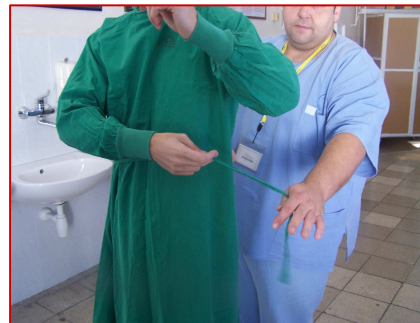


Figure 4. Wearing a surgical gown

Gloving

Gloving is assisted by a scrub nurse already wearing a sterile gown and gloves. Rules of gloving: the scrub nurse holds the glove towards you in a way that the palm of the glove is facing you. In our institute it is customary to wear the left hand glove first. In this case, put two fingers of your right hand into the opening and pull the inner side of the glove towards you. Slip your left hand into the glove. Then, with your gloved left hand catch the outer side of the right hand glove - which is now kept in front of you- to open it. Thrust your right hand into the glove. After both your hands are gloved you may then adjust your gloves so that they fit comfortably on the hands (Figure 5.).

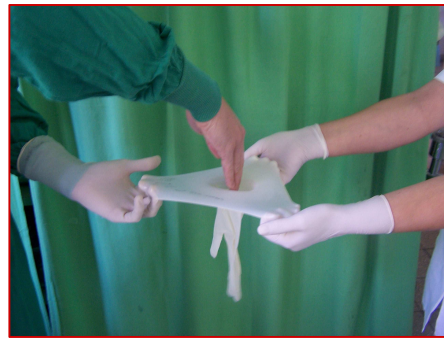
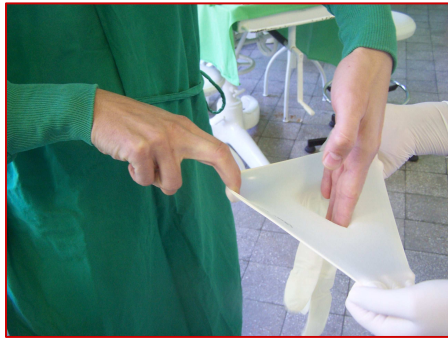
Figure 5. Gloving

3.7. Preparation of the surgical area

Bathing

It is not unequivocal that bathing lowers the germ count of the skin, but as regards elective surgery preoperative antiseptic showers/baths are compulsory. This should be done with antiseptic soap (chlorhexidine or quaternol) the evening prior to the operation.

Shaving

It must be done immediately prior to the operation, with the least possible cuticular/dermal injury; in this case, the wound infection rate is only 1%. Clippers or depilatory creams reduce infection rates to < 1%.

Preparation of the skin

Most commonly used disinfectants are: 70% isopropanol, 0,5% chlorhexidine (a quaternary ammonium compound), and 70% povidone-iodine.

Disinfecting and scrubbing of the surgical area

This is performed after the surgical hand scrub and before dressing. Scrubbing is performed outward from the incision site and concentrically. The prepped/disinfected area must be large enough for the lengthening of the incision/insertion of a drain. Based on the applied general regulations, Povidone-iodine (e.g. Betaisodona or Betadine) or alcoholic solutions (e.g. Dodesept) are applied 3 consecutive times. In aseptic surgical interventions the procedure starts in the line of the planned incision moving outwards in a circular motion, while in septic and infected operations it starts from the periphery toward the planned area of the operation. An area already washed is not returned to with the same sponge (Figure 6.).

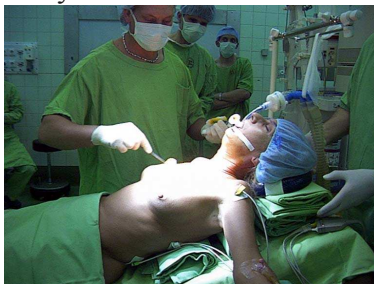

Figure 6. Disinfecting of the surgical area

Isolation of the operating area (draping)

After the skin preparation, the disinfected operating area must be isolated from the non-disinfected skin surfaces and body areas by the application of sterile linen textile (muslin) or sterile water-proof paper drapes and other sterile accessories/supplements. The main aim of isolation is to prevent contamination originating from the patient's skin. The isolation is generally done with the help of 4 pieces of the disposable sterile sheet, nondisposable permeable linen textile, or paper drape (the self-attaching surfaces of these latter, fix them to the patient's skin). In general surgical operations (e.g abdominal operations), the scrub nurse and the assistant use a specially folded first sheet (big sheet) to isolate the patient's leg. The second sheet (horizontal sheet) is used to isolate the patient's head. This sheet is fixed to the guard. Placement of the two side-sheets then follows. The isolated area is always smaller than the scrubbed area. After being placed on the patient, sheets can not be moved toward the operating area. Four Backhaus towel clips will fix the isolating sheets to the patient's skin at the surgical territory. The sheets are fixed to each other, to the gaurd, and to the Sonnenburg's table with towel clips (Figure 7.).

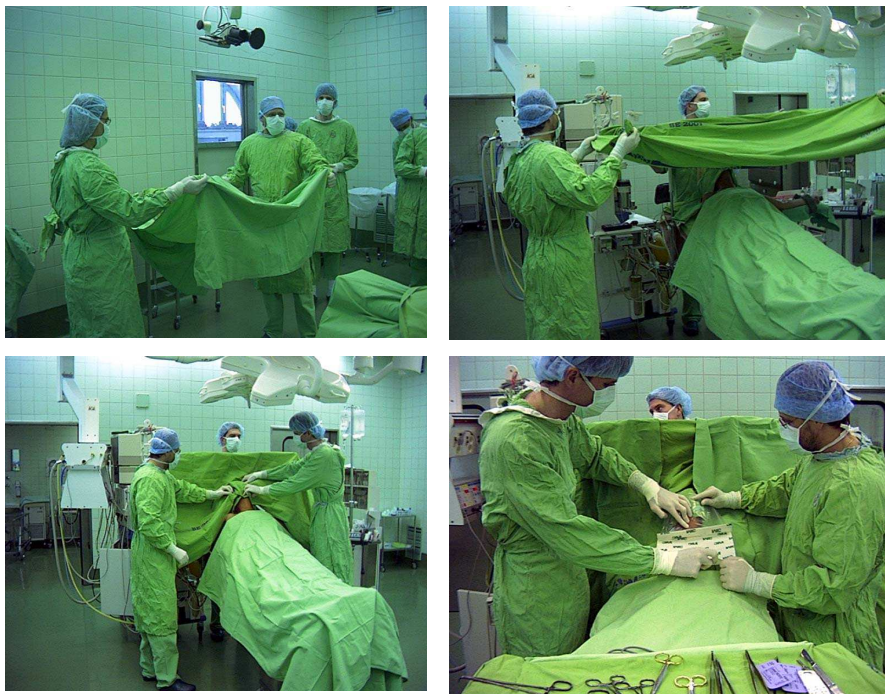

Figure 7. Isolation of the surgical area

4. BASIC SURGICAL INSTRUMENTS, SUTURE MATERIALS, SUTURING TECHNIQUES

4.1. Basic surgical instruments and their use

Surgical instruments are precisely designed and manufactured tools. They can be either disposable or non-disposable (e.g. reusable, resterilizable). The non-disposable tool must be durable, and easy to clean and sterilize. They should withstand various kinds of physical and chemical effects, namely body fluids, secretions, cleaning agents, and sterilization methods (e. g. high temperature and humidity). They are generally made of high-quality stainless steel. Chromium and vanadium alloys ensure the durability of edges, springiness and rustlessness. Some of these instruments are invented thousand years ago, but those which are invented in the last century have gone through developmental changes which made them suitable for present purposes. Instruments used in minimal invasive surgery were invented in the last 20 years, but they have gone (and are still going) through developmental changes according to our everyday demands. So the contemporary instruments are lighter, more aesthetic, and long-lasting.

Most everyday interventions can be performed with relatively few instruments which should be handled correctly. In many cases, not the lack of an instrument or the instrument itself is the cause of an unsuccessful intervention but the surgeon! So we should look for the cause of an unsuccessful operation first in ourselves and not in instruments.

Due to the constant improvements by surgeons and manufacturers, the number of instruments is so big that only their basic categories and the main representatives can be surveyed. Depending on their function, basic surgical instruments can be categorized into six groups. Some instruments (e.g. Péan) can have many functions. In such cases we categorize that instrument into only one of these six categories.

These six groups are as follows:

1. Cutting and dissecting instruments,
2. Grasping instruments,
3. Instruments used for hemostasis,
4. Retracting instruments,
5. Tissue unifying instruments and materials,
6. Special instruments.

4.1.1. Cutting and dissecting instruments

Their function is to cut or dissect the tissue and to remove the unnecessary tissues during the surgery. Scalpels or scissors are most frequently used instruments for these purposes. The following instruments also belong to this category: hemostats used to prepare the tissues, dissectors, diathermy pencil (mono- or bipolar diathermy or electrocautry), amputation knife, saws, and raspatories.

Scalpels

During the tissue dissection scalpels cause minimum traumatization of the tissue. Nowadays, instead of the conventional scalpel, disposable scalpels with a plastic handle or scalpels with a detachable blade are most commonly used. A disposable blade is attached to the resterilizable metallic handle before the operation (Figure 8.). It is used for 1) making an incision on the skin, 2) dissecting the connective tissues, and 3) preparation of a scarred tissue.

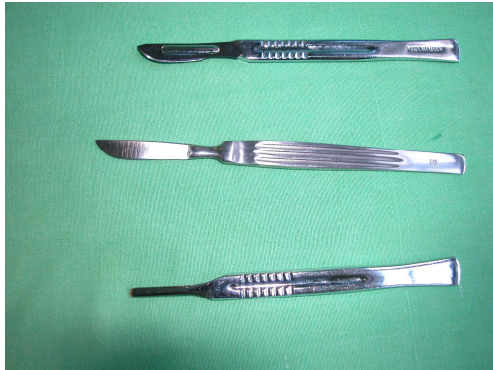

Figure 8. Type of scalpels

A. Handle with a disposable blade, B. Conventional scalpel, C. Handle

Wide-bladed scalpels with a curved cutting edge are used for incising skin and subcutaneous tissues. At all times, the skin incision should be done with scalpel because this will insure the proper adjusting of the edges which is a fundamental factor in healing process. Cutting with the whole length of the cutting edge (and not merely with its tip) can lead to less injury to the tissue. Thin-bladed, sharp-tipped scalpels serve for the opening of blood vessels, ducts, and abscesses (Figure 9.).



Figure 9. Blades with various sizes and shapes

Holding of the scalpel:

1. In long, straight incisions, the scalpel is held like a fiddle bow: the handle is gripped horizontally between the thumb and middle fingers while the index finger is staying above the handle. The ring and little fingers are holding the end of the handle.
2. In short or fine incisions, the scalpel is held like a pencil, and the cutting is made mostly with the tip (Figure 10.).

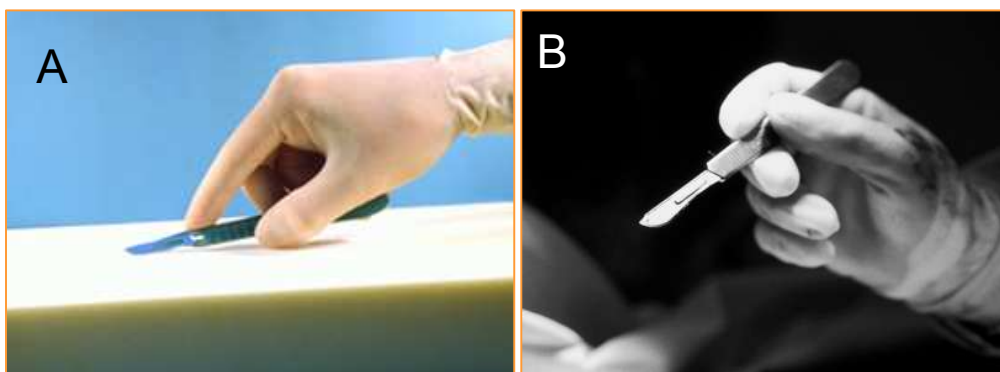


Figure 10. Holding of the scalpel

A. Fiddle bow holding, B. Pencil holding

Scissors

Next to the scalpel, scissors are most often used to dissect and cut tissues. Threads and bandages are also cut with scissors. Scissors can be of different sizes. Their blade can be straight, curved or angular. The tips of the blades can be blunt-blunt, blunt-sharp or sharp-sharp. The cutting is usually made by portion of the blade which is close to its tip (Figure 11. and 12.). Scissors are also suitable for blunt dissection and preparation of the tissues. In this case the scissors are introduced into the tissues with their tips closed. Thereafter, we open the scissors and do the dissection with the lateral blunt edges of the blades.

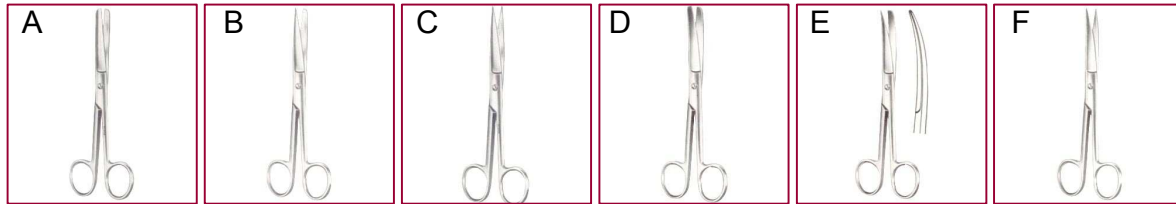


Figure 11. Scissors with various tips and blades: A. Straight blunt-blunt scissors, B. Straight blunt-sharp scissors, C. Straight sharp-sharp scissors, D. Curved blunt-blunt scissors, E. Curved blunt-sharp scissors, F. Curved sharp-sharp scissors

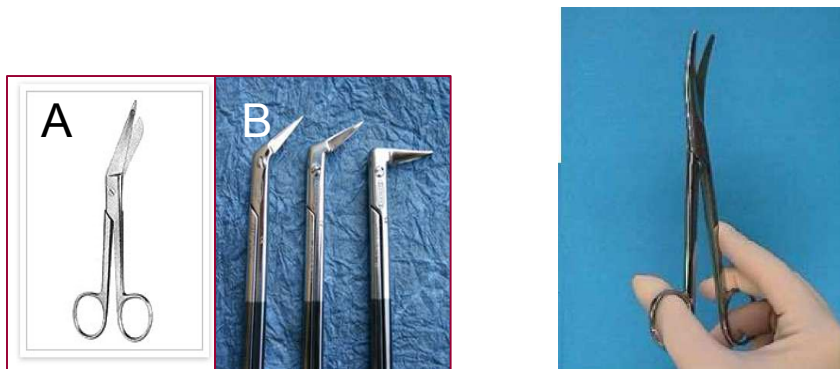


Figure 12. Scissors which are angled at the joints: A. Lister bandage scissors, B. Kneed scissors
Figure 13. Correct holding of the scissors (1st-4th rule of holding the instrument)

Correct holding of the scissors and all ring-ended instruments: the thumb and the fourth finger are inserted into the rings which are located at the handle, while the index finger is placed distally over the handle to stabilize the scissors (1st-4th rule of holding the instrument) (Figure 13. and 14.).



Figure 14. Correct holding of the ring-ended instruments with right and left hands

Hemostats used for tissue preparation: Péan clamp, mosquito clamp, abdominal Péan clamp

Instruments listed here are suitable for tissue preparation (dissecting instruments), grasping (grasping instruments), as well as haemostasis. They are used for blunt dissection and preparation of the tissues. In this case they are introduced into the tissues with their tips closed. Thereafter, we open them and do the dissection with the lateral blunt edges of the instrument.

Structurally, they are similar to the scissors. There are rings at the proximal end of the handle. A little bit below the rings you can find the locks, which are used to close the handle. Péan clamp, mosquito clamp, and abdominal Péan clamp are traumatic (crushing) clamps (or forceps) because their grasping parts are serrated (Figure 15.).

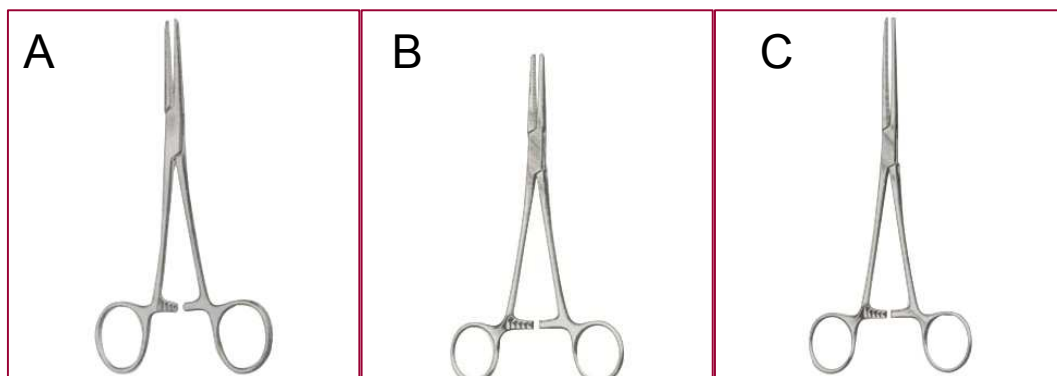


Figure 15. Hemostats used for preparation

A. Péan clamp, B. Mosquito clamp, C. Abdominal Péan clamp

These instruments can stop bleeding when applied after the preparation of the vessel and before its cutting (planned hemostasis) or used to grasp and clamp the end of a cut vessel which is bleeding. These are ring-ended instruments. So the 1st-4th rule of holding the instruments is applied here. The lock can be opened by pressing down one of the finger rings with our thumb while elevating the other one with the ring finger. In this manner the interlocking teeth are moved from one another. We should learn how to use such these instruments with both of our hands. At the time of their removal we should avoid their twitching and handle them carefully to avoid the

tearing of the tissues.

Dissector

Long-handled, ring-ended instrument, which is bended 90° at its distal part. It may or may not have the interlocking teeth. We use them to dissect and prepare the tissues atraumatically (Figure 16.)

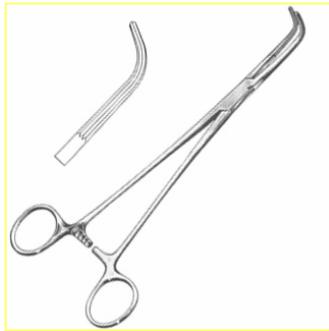

Figure 16. Dissector

Diathermy knife

It dissects the tissues with the help of the heat which is generated by the electric current. Its advantage is that during the dissection the heat can also coagulate the small vessels and in this way cutting and hemostasis are happening simultaneously. The diathermy can be either mono- or bi-polar. When the electric current is passing between the two parts of the instrument we call it the bipolar diathermy (e.g. bipolar forceps) and when it passes between the instrument and the indifferent electrode -which is placed beneath the back or one of the lower limbs of the patient- it is called the monopolar diathermy (e.g. electrocauter or electrocautery knife).

In general surgery the monopolar diathermy is used most commonly. Considering the fact that during the dissection it also coagulates the small vessels, the preparation phase of the the operation will become easier and shorter. In a patient with a pacemaker, the electric current of diathermy can cause arrhythmia. The old type of pacemaker needs to be adjusted prior to the surgery, while with the modern pacemakers this problem does not exist. It is not advisable to use the diathermy for making a skin incision because it can burn the skin and lead to its necrosis. You should be careful when using it during the operation and for purposes other than skin incision. Because the electric current and heat can be conducted to the skin by any metallic instrument and this itself may again be a cause for the skin necrosis. With use of various voltage and amperage you can only coagulate (the so-called "coagulation grade" which can be achieved by pressing the blue bottom of the electrocautery). With increasing the voltage and amperage of the device it can become suitable for tissue dissection as well (the so-called "cutting grade" which can be achieved by pressing the yellow bottom of the electrocautry). These two types of function can also be achieved with use of a foot pedal. In this way other metallic instruments (e.g. forceps) can be used which can lead to a more precise and faster operation (Figure 17. A, B, and C).

In the case of a bipolar diathermy there is a need for smaller voltage and amperage. It makes possible to perform a more precise work and the size of the burned area is smaller as well. The wire of the bipolar forceps is connected to the diathermy device (Figure 17. B and D).




Figure 17. Monopolar and bipolar diathermies

A. Monopolar diathermy with its indifferent electrode and hand portion, B. Diathermy device (for both mono- and bi-polar diathermies, C. Foot pedal of the monopolar diathermy, D. Bipolar forceps

Ultrasonic cutting device

Ultrasonic cutting device (Ultracision[®]) is using the ultrasound to cut and coagulate the tissues. It is working similarly to the diathermy but the ultrasonic device does not cause a thermic injury. It makes possible to have more precise movements during operation (Figure 18.).



Figure 18. Ultrasonic cutting device and various shapes of its hand portion

CUSA (Cavitron Ultrasonic Surgical Aspirator)

The ultrasonic vibrating knife selectively crushes and sucks the tissues which contain high quantity of water and low amount of collagen; meanwhile it is taking care of other tissues (e.g. vessels and nerves). During operating on solid organs the use of this instrument leads to less blood loss and tissue damage (no thermic injury!), as well as better viewing (Figure 19.).

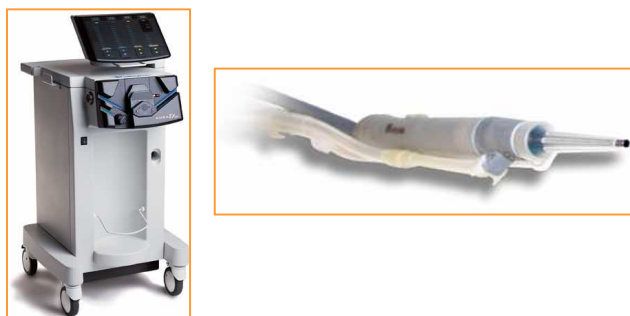


Figure 19. CUSA and its hand portion

LASER (Light Amplification by Stimulated Emission of Radiation)

CO₂ laser is useful for superficial treatment, while the neodymium-YAG-laser is good for 3-5 mm deep areas. Use: cutting, coagulation, vaporization, selective obliteration of the diseased tissues, and palliative treatment of the nonresectable gastrointestinal tumors.

Amputating knife, saws, raspatories

Amputating knives of different sizes are manufactured with one- or two-sided cutting edge for limb amputations. Various types of saws are suitable for cutting the bones. One side of the raspatory is smooth while its other side is rolled up. The semi-circle end of it is a little sharp. Use: blunt separation of the periosteum and connective tissue from the surface of the bone.




Figure 20. Amputating knife, various types of saws, raspatory

4.1.2. Grasping instruments

These instruments are used to grasp, pick up, and hold the tissues or organs during the operation for the purpose of having a better retraction, a more precise incision and a more effective movement. The minimum requirement for most of them is to produce as little as possible injury to the tissue or organ while grasping it. The only exception for this is related to those instruments which are used to crush the tissues. Forceps, towel clamps, vascular clamps, needle holders, organ holders, and sponge holding forceps belong to this category.

Non-locking grasping instruments: thumb forceps

These are the simplest grasping tools. Forceps are made of different sizes, with straight, curved or angled blades. They can have blunt (smooth forceps), sharp (splinter forceps), or ring tips (Figure 21.). Forceps are used to hold the tissues during cutting and suturing, to retract tissues for exposure, to grasp vessels for electrocautery, to pack sponges and gauze strips in the case of bleeding, to soak up the blood, and to extract foreign bodies.




Figure 21. Forceps

A. Smooth forceps, B. Toothed forceps, C. Splinter forceps, D. Ring forceps (brain tissue forceps), E. Dental forceps

Forceps should be held like a pencil. They grip when compressed between the thumb and index finger. This makes possible the most convenient holding, the finest handling and free movements (Figure 22.). In this way the forceps actually act in a manner as if our thumb and index finger are elongated. Any other type of holding is not acceptable in surgery.

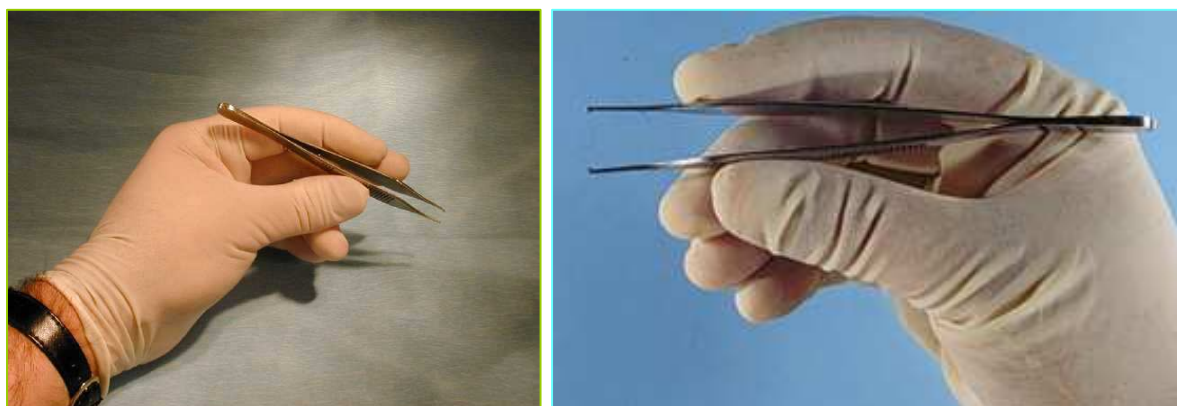


Figure 22. Correct holding of the forceps

As a general rule, always use such that kind of forceps with which you can perform the desired work with as little as possible injury to the tissue. The teeth of toothed forceps prevent tissues from slipping. Accordingly, only a small pressure is required to grasp tissue firmly. Thus, to grip skin and subcutaneous tissues, the toothed forceps is used most frequently. However, vessels and hollow organs must not be grasped with them due to the risk for bleeding and perforation. For these purposes, or for holding sponges or bandages, the smooth forceps should be chosen. These have blunt ends with coarse cross-striations to give them additional grasping power. Skin gripped firmly with smooth forceps for a prolonged period can necrotize. The forceps is not suitable for a continuous grasping of the tissues. To perform this, we can use the various tissue graspers, retractors, and tension sutures. The hands and fingers of the assistant can also help us for the same purpose.

Towel-holding clamps

These serve to fix the draping towels to the ether screen, to one another, and to the skin of the patient. These locking grasping instruments serve to fix the grasped object. In the case of the Schaedel towel clip the springiness of the distal part, while in relation to the Backhaus towel clip the ratchet lock of its proximal portion serves to fix the grasped draping towel (Figure 23.).

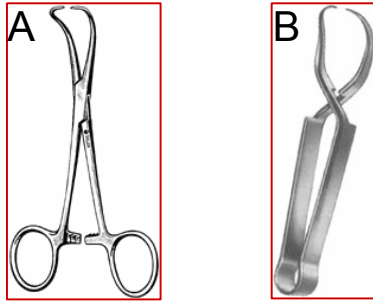


Figure 23. Towel clamps

A. Backhaus, B. Schaedel towel clamps

Hemostatic forceps (hemostats)

These instruments are the main means of establishing hemostasis during an operation. They are used to stop bleeding by grasping and clamping the ends of the cut vessels or for preventive hemostasis by applying them before cutting the vessel.

Kocher and Lumnitzer clamps are traumatic hemostatic forceps. The grasping part is straight or curved and there are teeth in the inner portion of it (Figure 24.). The Péan clamp, abdominal Péan clamp and mosquito clamp can also be listed here. In these cases the grasping portion can also be straight or curved and its inner surface is serrated (Figure 15.).

The atraumatic hemostatic forceps are applied if the damage to the vessels or tissues must be avoided because their function is expected later, e.g. if the circulation is to be restored after their removal. The Dieffenbach forceps (Bulldog clamp) and the formerly used Blalock clamp - which had rubbers at its grasping part and there was a screw at the proximal part for fixing it - belong to this group. The Satinsky tangential occlusion clamp permits a partial occlusion of the lumen of the larger blood vessels. In this way, while an anastomosis is made, the blood flow below the clamp is undisturbed (Figure 25.).

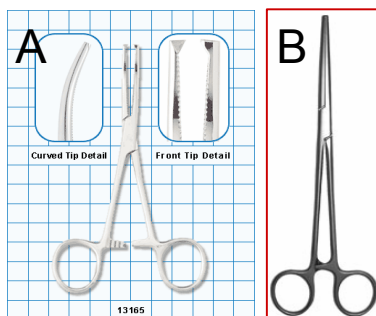


Figure 25. Traumatic hemostatic forceps

A. Kocher, B. Lumnitzer clamps

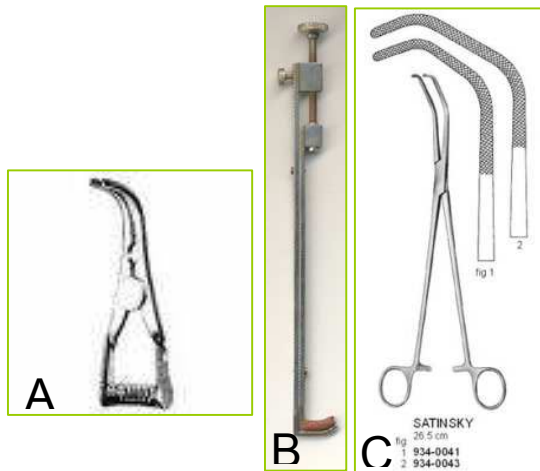


Figure 25. Atraumatic hemostatic forceps
A. Bulldog, B. Blalock, C. Satinsky clamps

Needle holders

In modern surgery suturing is performed almost exclusively with curved needles that are held with needle holders designed for the grasping and guiding of needles. The needle holders grip the needle between the jaws, specially developed for this purpose; they usually have a ratchet lock. The Mathieu needle holder has curved shanks with a spring and a locking mechanism. It should be held in the palm. The Hegar needle holder resembles a hemostatic forceps, but the shanks are longer and the relatively short jaws are made of a hard metal. The serrations are designed to grip needles. During suturing in deep layers, needle holders with long shanks should be used (Figure 26. and 27.).

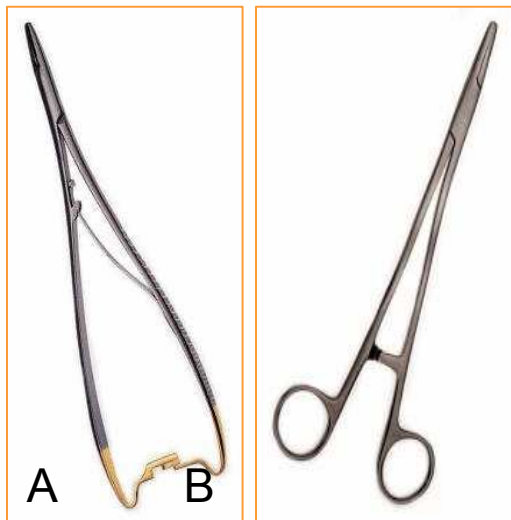

Figure 26. Needle holders
A. Mathieu, B. Hegar needle holders

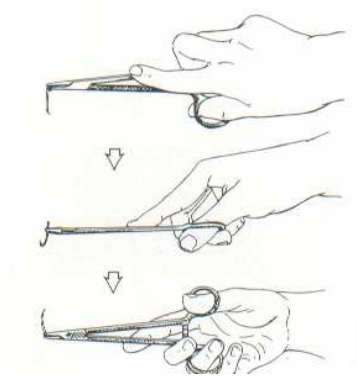


Figure 27. Correct holding of the Hegar needle holder (1st- 4th rule of holding the instruments)

Tissue-grasping forceps

These are special instruments used for delicate grasping and holding of the organs. The Klammer intestinal clamp, the Allis clamp (used to grasp and hold the lung), gall bladder forceps, and the Babcock forceps can be listed here (Figure 28.).

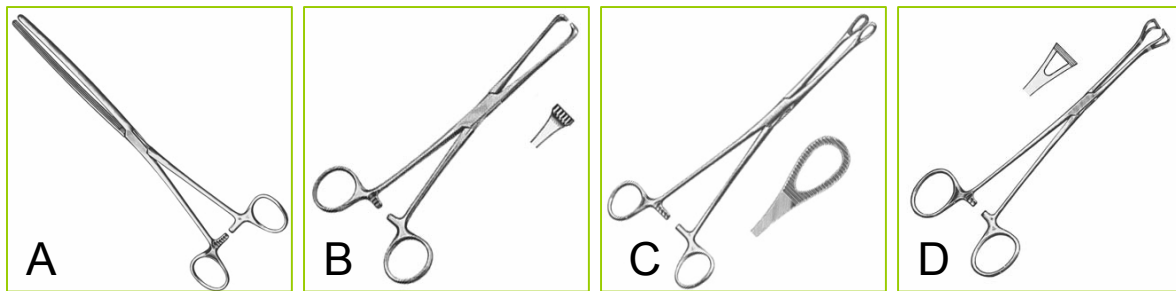


Figure 28. Organ holders

A. Klammer, B. Allis clamp, C. Gall bladder forceps, D. Babcock forceps

Sponge-holding forceps

In general surgery, it is used to grasp the swabs for disinfecting the surgical area prior to operation, or removing the blood and secretions from surgical territory during operation. Swab together with the sponge-holding forceps are called the handled swab. The sponge-holding forceps are also suitable for creating various subcutaneous tunnels (Figure 29.).

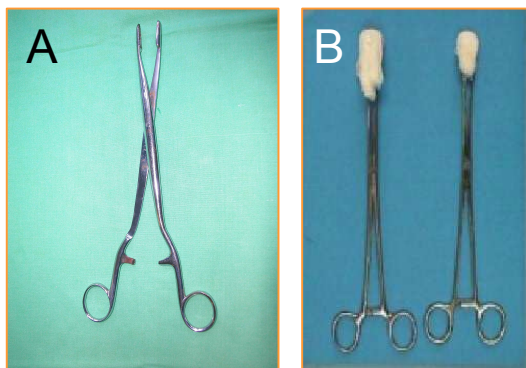


Figure 29. Sponge-holding forceps (A) and handled swab (B)

4.1.3. Instruments used for hemostasis

They act mechanically or thermally to stop bleeding at the site of incision or in the surgical territory. The important members of this group are: vascular clamps (Péan, mosquito, abdominal Péan, Kocher, Lumnitzer, Satinsky, bulldog), electrocautery knife, various ligation needles and directing probes (e.g. Deschamp ligation needle, and Payr probe), and argon beam coagulator.

Deschamp ligation needle and Payr sonda (probe)

The Payer probe is used to dissect the area which is located beneath the vessel. Following this, it is kept under the vessel and the Deschamp ligation needle is directed under the vessel and above the probe. Suture material is passed through the hole found at the end of the Deschamp needle which is then directed back from under the vessel. In this manner, we can ligate the desired vessel (Figure 30.).

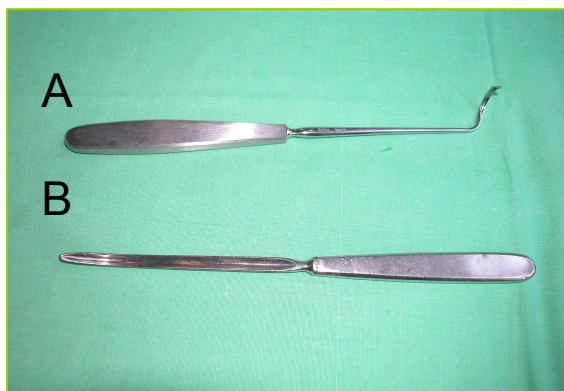

Figure 30. Deschamp ligation needle (A) and Payr probe (B)

Argon beam coagulator

It is one of the newest instruments for hemostasis during the operations performed on solid organs. It makes possible to do a monopolar coagulation with a so-called "no-touch technique". Its penetration depth is small, for this reason the hemostasis is rapid and effective (Figure 31.).

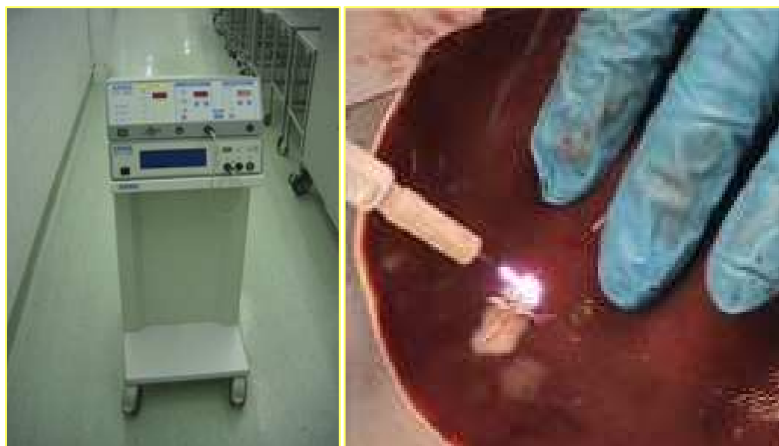

Figure 31. Argon beam coagulator

4.1.4. Retracting instruments

Retractors are used to hold tissues and organs aside in order to improve the exposure and hence the visibility and accessibility of the surgical field. Hand-held retractors (e.g. skin hook, rake, Roux, Langenbeck, visceral and abdominal wall retractors) are held by assistant. They cause minimal tissue damage because the assistant maintains tension on tissues only as long as necessary. When applied properly, self-retaining retractors (e.g. Weitlaner self-retaining retractor, Gosset self-retaining retractor) are of great help, but care should be taken not to damage the tissues when they are placed and removed (Figure 32.).

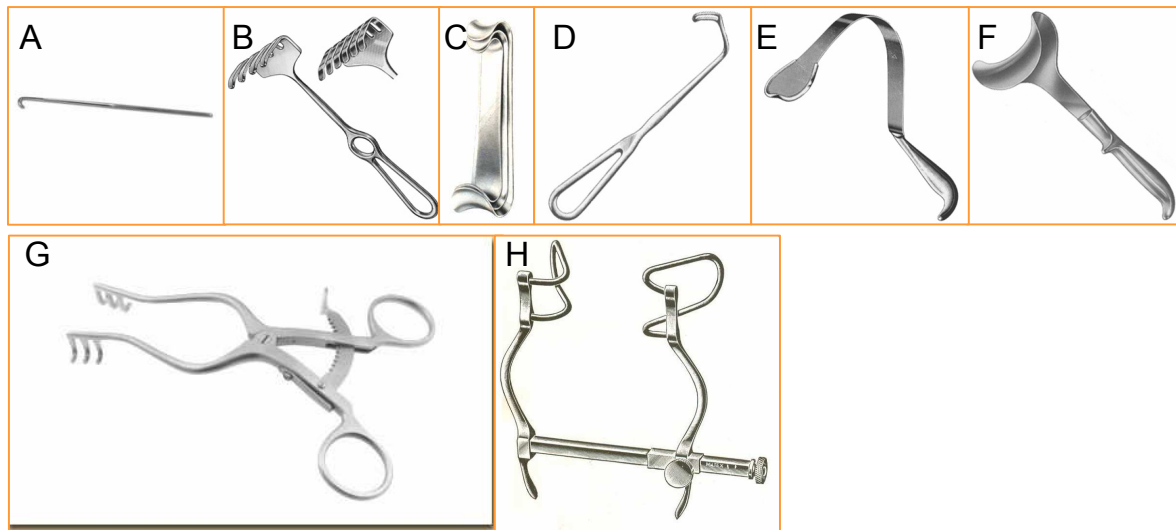


Figure 32. Retracting instruments

A. Skin hook, B. Rake retractor, C. Roux retractor, D. Langenbeck retractor, E. Visceral retractor, F. Abdominal wall retractor, G. Weitlaner self-retaining retractor, H. Gosset self-retaining retractor

4.1.5. Wound-closing instruments and materials

The instruments (and materials) used to unite the tissues belong to this group. The basic principle for wound healing is the proper and tension-free approximation of tissues. Next to this, any dead space should be avoided, as well as there should be an appropriate blood supply of the tissues. The number of stitches (or clips) should be as little as needed. The surgical needles, suture materials, needle holder (see "grasping instruments"), staplers, clips, and adhesive tapes belong to this group.

Surgical needles and sutures

Detailed discussion of this part can be found in section 4.2.

Staplers

Suturing of a big surgical area is exhausting. Beside this, the pulling of the tissue can be a cause for a later insufficiency and the operation time is also increased in the case of the hand suturing. Due to these reasons and especially in intestinal or lung surgeries, the staplers are essentially important. The staplers can be either linear-which produce the suture row along a straight line -or circular- which are used to make anastomosis between two hollow organs (Figure 33.).

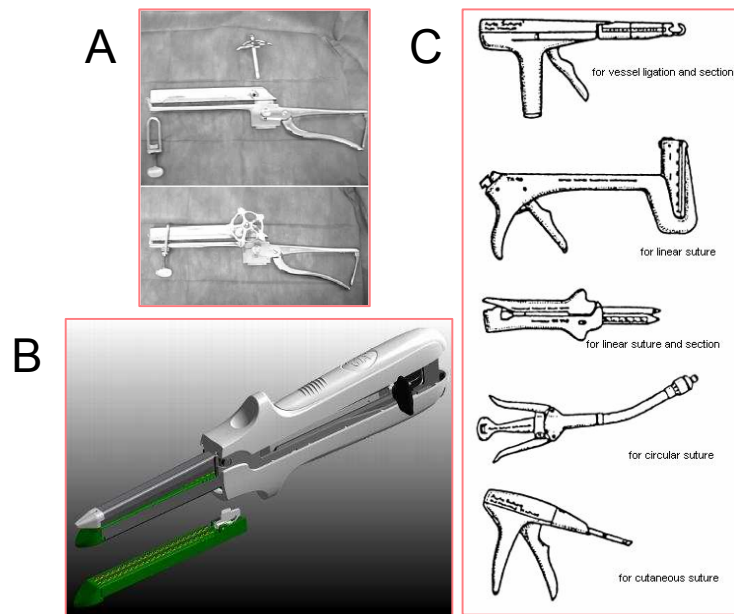


Figure 33. Staplers

A. Petz stapler, B. Linear stapler, C. Staplers with various shapes for different uses

Clips

The classic Michel clips -which can be used with the help of Michel clip applicator and remover-, are used to close a skin wound (Figure 34.). Clips are generally useful for closure of any luminal structure (e.g. vessel, duct).

Other uses of metallic clip:

- in the wound stapler, which makes possible the atraumatic and fast closure of the wound
- in hemostasis (The metallic clips can occlude the lumen of the vessel well)
- the metallic clip can be seen in x-ray film. So it can be useful for various markings (e.g., the bed of a tumor)

Appearances of the CT and MRI have changed our views relating to the use of the metallic clips. In the case of CT, the clip disturbs the picture only in the vicinity of it and so the examination can be done. In the case of MRI, the implanted or used metal (e.g. iron, nickel, cobalt) makes impossible to perform the examination because these metals can move in a magnetic field and in this way a vascular clip can fall down or the intracranial clips can become wandering. Due to spreading of the MRI examinations, it is advisable to use the non-magnetic clips (e.g. titanium, platinum, and absorbable clips).

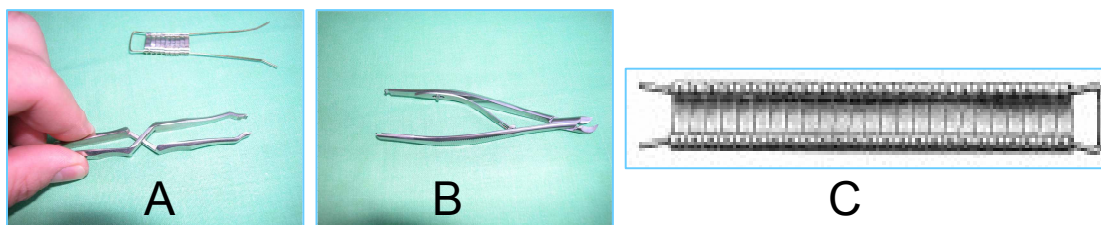


Figure 34. Michel clip applicator (A), Michel clip remover (B), Michel clips (C)

Self-adhesive strips

Self-adhesive strips (Stri-Strip) can also unify the tissues. They can be applied in the case of smaller wounds not requiring suturing, when the wound edges can easily and well be approximated. They are also used to fasten the subcuticular sutures. Their use is easy and fast but they can only be used in dry and non-secreting areas (Figure 35.).

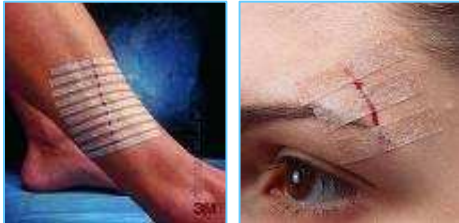

Figure 35. Self-adhesive strips

Surgical adhesives

They are usually produced from fibrin, collagen or thrombin and induce the last phase of blood coagulation, so that a firm fibrin mesh is produced. Application fields: for hemostasis in operations done on solid organs, and to close the place of air leakage in lung surgeries. Disadvantages: in infected wounds, they can increase the degree of infection and lead to abscess formation.

4.1.6. Special instruments

Those instruments which are not used routinely during surgical interventions belong to this group.

Volkman curette

They have various sizes. The edges of the distal spoon-shaped part of this instrument are sharp which make possible to remove the tissues. The main application areas: skin tags (e.g. condyloma, wart) removal, to clean the base of the infected wound, and to remove the infected bone in the case of osteomyelitis (Figure 36. A).

Instruments used in bone surgeries

They are helpful to perform operations on the bones in orthopaedic surgery and traumatology (Figure 36. B and C).

Round-ended probe

They are straight or curved malleable metallic rods with various sizes. Their end is generally rounded. Use to gauge depth or direction of a sinus or cavity by inserting it there in (Figure 36. D).

Payr clamp

We use it before resecting of the intestine. The essence of the crushing is to apply equal pressure over the serosal layer whereby we can avoid the tearing of the serosa before application of the ligature (Figure 36. E).



Figure 36. Special instruments

A. Volkman curette, B. Mallet, C. Chisels, D. Round-ended probe, E. Payr clamp

Suction set

It is used to suck the larger amounts of the blood and secretions from the surgical territories. This set consists of a resterilizable suction tip, a tube and a nonsterile container. The upper end of the container is connected to a central suction system.

X-raying set

It is mainly used during the operations done on bones. It makes possible to check the position of the bones and the implanted metals during the surgery.

Implants, prostheses

The metallic screws and pins, joint prostheses, hernial meshes, vascular grafts and silicon implants (used in breast surgery) belong to this group.

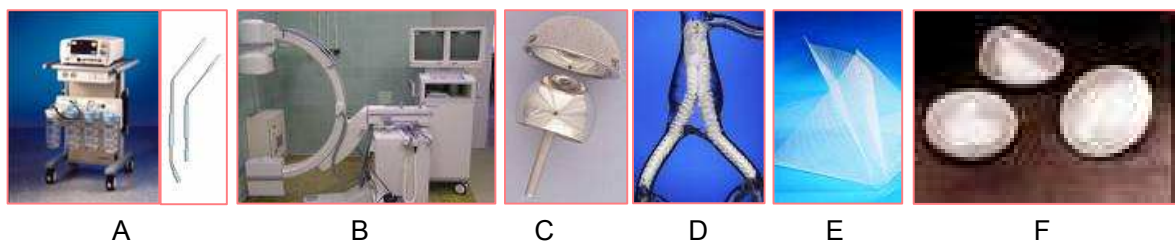


Figure 37. Special instruments

A. Suction set and suction tips, B. X-raying set, C. Metallic joint prosthesis, D. Vascular grafts, E. Hernial meshes, F. Breast implants

4.2. Suturing tools and materials

4.2.1. Surgical needles

In the history of healing, many materials were used as the surgical needles (e.g. bone, fish bone, and acacia thorn). Since 19th century the metallic needle-which was non-disposable for a long period of time-has been used.

The criteria for an ideal needle:

- should be made of the stainless steel with a high quality, which causes minimal tissue reaction,
- should be thin as much as possible (but this should not affect the strength of the needle),
- can be fixed and directed in a stable manner on the needle holder,
- can direct the suture material with a suitable assurance and a minimum tissue injury,
- should be sharp enough to pass through the tissues (with a minimum tissue resistance)
- should be stiff enough to resist bending but at the same time it should be flexible enough not to

- break,
- should be steril (and easily sterilizable).

Nowdays two basic types of the needle can be found in the market: the conventional (close-eyed and the French-eyed needles) and the atraumatic needles. The conventional needle needs to be threaded. In such a this case, the needle and the two arms of the thread pass through the tissue and this can causes trauma to the tissue. Other disadvantages: threading time, restrilization, need to take care of needle tip, the danger of corrosion and untying (Figure 38.).



Figure 38. Conventional needles: close-eyed (A) and the French-eyed (B) needles

The appearance of the atraumatic needle was a revolutionary innovation in surgery. Because the triple thickness present at the eye of the needle (e.g. the thickness made by needle and 2 arms of the thread) is obliterated in the atraumatic needle. This can cause the least tissue trauma. In the past to manufacture an atraumatic needle they used to insert the thread into the eye of the needel and then flatten this part of the needle completely. Nowdays the diameter of the needle-thread combination is smaller than that of the thread. This property is well used in vascular sutures where the diameter of the thread is larger than the hole which is produced by the needle and so the tissue around the thread surrounds it tightly and prevents leakage of the secretions or blood. Other advantages: no threading time, no need for reesterilization, no need to take care of the needle tip, and no danger for corrosion and untying. The Proper handling of such a needle is also important because strong pulling of the thread can separete it from the needle (Figure 39.).

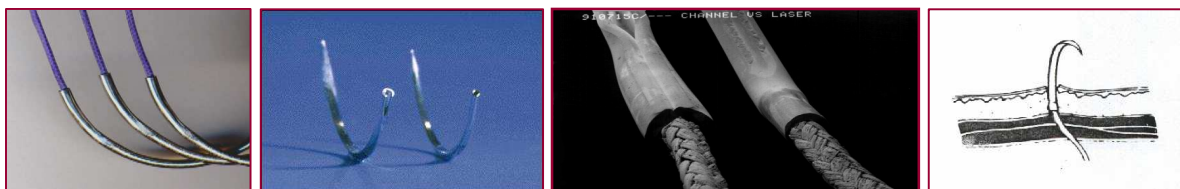

Figure 39. Atraumatic needle




Figure 40. In cross-section, the needels can be circular (A) and cutting (B)

Based on the cross-section of the needle there are 2 types of needels: circular and cutting (Figure 40.).

The circular needle has 3 main groups: taper-point, taper-cutting, and blunt taper. The term "circular needle" classically refers to "taper-point circular needle". Both the tip and the body of the needle are circular. Such this needle separate the tissue fibers without cutting them up. The taper-point circular needles are generally used in easily penetrable tissues (e.g. peritoneum, abdominal organs, myocardium, and subcutaneous tissues)(Figure 41. A).

At the tip of the taper-cutting needle there are three cutting edges. These edges gradually become flattened and are finally obliterated at the body. These needles are developed to sew the sclerotic, scarry, and calssified tissues (e.g. scarry fascia, connective tissue, periosteum, tendon, and calssified vessels). The diameter of the cutting and the penetration caused by cutting edge are smaller than the diameter of the thickest part of the needle (and that of the inserted thread as well). In this way, even after pulling of the thread through the tissue there will not appear any dispropotionality between the stitch channel and the thread. The thread will compeletly fill the stitch channel and -in relation to the luminal structures- this prevent the body secretions, blood, and infected materials to enter from one space to the other one (Figure 41. B).

The blunt taper needels have a circular body and a blunt tip. This needel serves for: preventing the danger of the needelstick injury (especially important in patients infected with HIV or hepatitis virus) and making possibilty to do suturing in a chronically ill patient with a less chance for needelstick injury of the surgeon or assistants, suturing those solid organs which have blood and lymph vessels, or bile and urinary ducts. While passing through the tissues, a blunt-taper needle pushes the delicate structures aside and does not cause a separation in their continuity. It merely produces a slit in the soft connective tissues and solid organs (Figure 41. C).

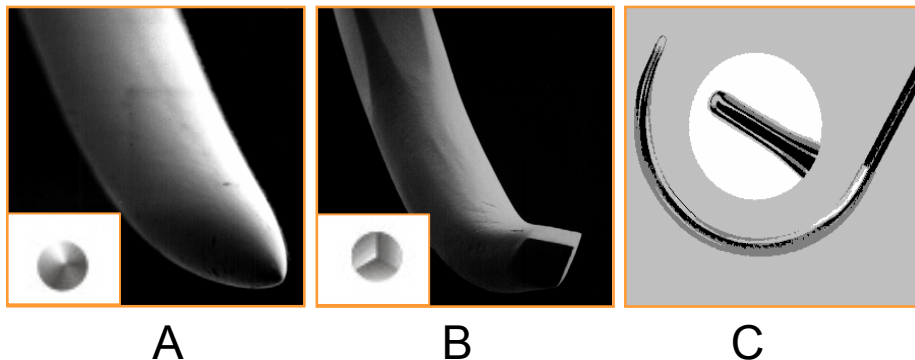


Figure 41. Circular needles

A. Taper-point, B. Taper-cutting, C. Blunt-taper

Most cutting needles have 3 cutting edges. The cutting edges are made somehow that they lead to a minimal tissue injury while the needle is passing through the tissue. These needles are suitable for sewing the tough structures (e.g. skin and scarry connective tissues). There are 3 basic types of it: conventional cutting, reversed cutting, and spatula-shaped cutting needles.

In the conventional cutting needle the third cutting edge is facing the internal part of the curved body. In cross-section, we get an imaginary triangle which apex is the middle point of the needle. In the tissue this apex is locating towards the edge of the wound and due to this the suture material, which is located at the edge and is pulled strongly, can lead to tearing of the tissue. In the case of the soft tissues the slamming of the suture material can happen (Figure 42. A). In such cases we use the reversed cutting needle which third cutting edge is facing the external part of the curved body. In cross-section, the base of the triangle is facing the internal part of the curved

body. In the tissues, this is locating towards the edge of the wound while the apex is facing away from it. In this way, the suture material will be located in penetrating channels of the needle which are actually parallel with the wound edges and this eliminates the "cutting through tissue" effect of the knotted sutures (Figure 42. B). The spatula-shaped needle is used in ophthalmology to perform the atraumatic penetration between the different layers (Figure 42. C).

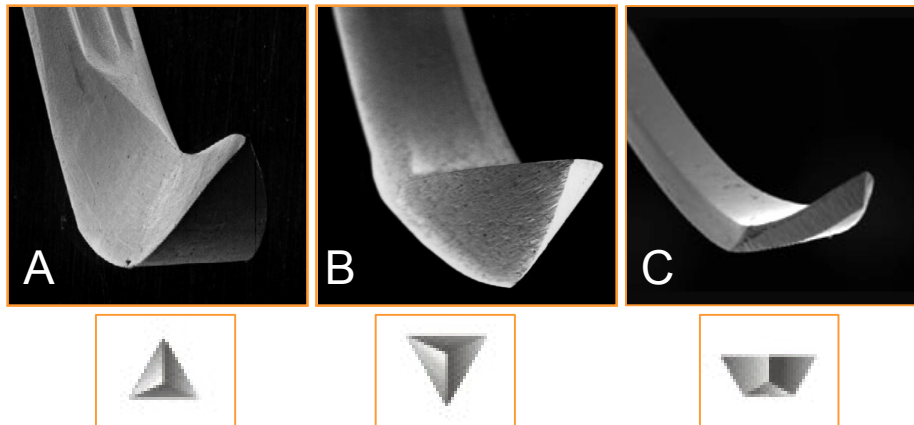


Figure 42. Cutting needles

A. Conventional cutting needle, B. Reverse cutting needle, C. Spatula-shaped cutting needle

The body of the surgical needles can be of various shapes, which specifies their use. We have straight (tendon suturing), ski-shaped (laparoscopic suturing), and curved needles. Based on their curvature, 1/4 circle, 1/2 circle, 3/8 circle, 5/8 circle, and combined-curved needles are discerned. This latter one has a parabolically curved body and is bended along another axis as well (Figure 43.).

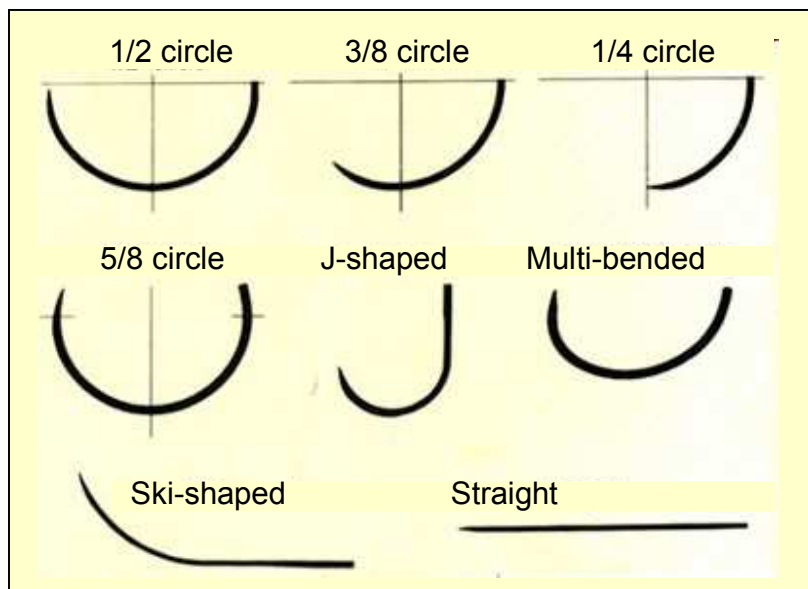


Figure 43. Shape of the needle

4.2.2. Suture materials

They are used to unify the incised tissues and to ligate the vessels. In the past, they used many materials as suture materials. Examples include: plant fibers (flax, hemp, cotton, bark), animal tissues (kangaroo's tendon, sheep intestine), metal fibers (silver, gold), and sterilized human hair. Sir Moynihan, the president of the British Royal College of Surgeons has already addressed the criteria for an ideal suture material in 1912. According to his opinion, they are as follows: suitable for any surgical intervention, easy handling, high tensile strength, knot security, monofilamentous structure, causing minimal tissue reaction, having a definable absorbency time, easy to resterilize, and cheap. Naturally, there is no suture material which can fit all these criteria. There is no ideal suture material but nowadays there are some suture materials which fit many of the above-mentioned criteria. The suture material is chosen based on the physical and biological properties of it, rhythm of the wound healing process, and the factors which are present in the patient (e.g. obesity, infections). The most important properties of the suture materials are as follows: 1. physical properties: caliber, tensile strength, elasticity, capillarity, structure, water absorbent capacity, sterilizability 2. application properties: flexibility, capability to slip in tissue, knotting properties, knot security 3. biological properties: absorbent capacity.

Threads are classified according to the origin of the material (natural or synthetic), the structure (mono- or multifilament), and absorbability (absorbable or nonabsorbable).

Natural and synthetic threads

The suture materials are made of natural or synthetic materials. Nowadays (and in many aspects of the life), we are experiencing the renaissance of using the natural substances. Concerning the surgical threads, however, it does not seem to be the same. Table 1 summarizes the advantages and disadvantages of these two types of thread. The main disadvantage of the natural substances is that they contain natural proteins (plant or animal origin). It is well-known that the elimination of the foreign proteins is the basic defensive function of the body. The absorption of these natural substances is done by the enzymatic way. It means that the proteolytic enzymes released from macrophages, neutrophils, and phagocytes will digest these substances. This process leads to a strong inflammatory cellular activity as well.

Most synthetic suture materials are inert and cause only small reactions in the living tissues. Their absorption is done by hydrolysis. It means that there is no need for the cellular elements and proteolytic enzymes. The molecules of these materials are simply disintegrating while H₂O is released. In this way, they cause less tissue reaction than natural materials.

Table 1. Comparison of natural and synthetic suture materials

| | Natural materials | Synthetic materials |
|---------------------|---|--|
| Advantage | Good handling Easy and good knotting | Economic Absorption by hydrolysis (predictable) Strength |
| Disadvantage | Tissue reaction Enzymatic absorption (unpredictable) Purchase, screening, controlling | Handling of Synthetic monofilaments is difficult |

The degree of tissue reaction depends on the substance of the thread. Example: chromic catgut and catgut are very strong, linen, silk, and polyamide are average, Teflon and polyester are moderate, polypropylene, polyglycolic acid, polydioxanone, steel and tantalum are minimal. Suture materials made of natural substances are still used but in surgery of the 21st century the use of the synthetic suture materials is considered to be modern.

Mono- and multifilament suture materials

Based on the structure, we have monofilament threads (having only one filament or fiber) and multifilament or braided threads (having more than one filament)(Figure 44. A and C). Table 2 summerizes their advantages and disadvantages.

Monofilaments have smooth surfaces and so can pass easier through the tissue causing fewer traumas. They do not lead to serrating (or sawing) phenomenon either. Due to rasping effect of the thread there exists a space between the thread and tissue cells. The bigger this space is, the more extensive the inflammatory (and later on fibrotic and possibly infectious) response is. Bacteria, viruses, and fungal spores can get engaged into the fibers (filaments) of a multifilamentous thread and so can easily be taken from one place to the other. The tumor cells can also adhere to the fibers of a braided thread. Happening so, this kind of thread can easily spread the cancerous cells to the healthy area. In addition to these, the braided threads -based on the capillary principal and differences in the osmolarities- can cause the tissue secretions, and electrolytes (and together with these microorganisms, and cellular elements) to go from one space to the other one (Figure 44. D).

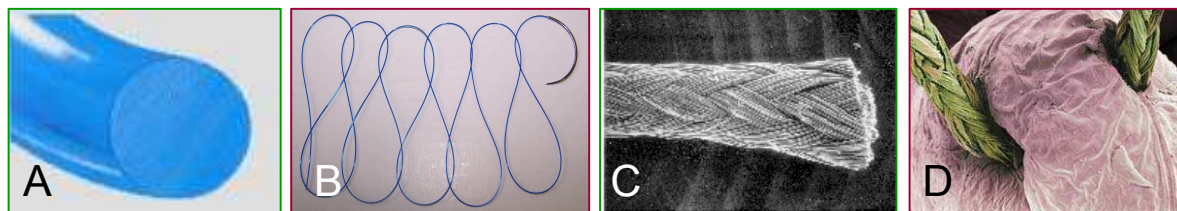


Figure 44. Schematic picture of a Monofilament thread (A), Thread memory (B), Multifilament thread (C), Magnified picture of a multifilament thread inside the tissue (D)

Table 2. Comparison of mono- and multifilament threads

| | Monofilament thread | Multifilament(braided) thread |
|---------------------|---|---|
| Advantage | Smooth surface Smaller friction Smaller resistance Smaller tissue injury No spreading of bacteria No capillarity Not transporting the tumor cells | Strength Softness and flexibility Easy handling Keep the knots well (knot security) |
| Disadvantage | Weaker Stiffer and more brittle More difficult to handle and make knot Thread memory (Figure 44. B) | Stretching Tissue drag, serrating Tissue trauma Spreading of bacteria Capillarity Transporting the tumor cells |

The multifilament threads are generally used when the knot security and tensile strength are of great importance. Examples include: ligation, transfixation, placing the prosthesis, joint fascia, and prosthetic valves. In minimal invasive interventions, plastic surgeries, suturing of delicate and fine structures, unifying the hollow organs and tissues for avoiding the transport of bacteria and the capillarity, as well as in oncological surgeries we prefer to use the monofilament threads. Many multifilament threads are coated. This let them preserve the characteristics of the

monofilament threads at least externally but at the same time we can get their advantages of being braided. Manufacturing of monofilaments with better and better mechanical properties lead to improvement of handling and knotting difficulties of these threads.

Absorbable and non-absorbable sutures

Some of the suture materials are sooner or later disappearing and we find no sign of them in the body. These are called the absorbable suture materials. However, the others will stay in their place of insertion –without or with some changes- forever. These latter threads are called the non-absorbable ones. Their comparison is shown in Table 3.

The suture materials are actually needed till that time when the scar tissue is formed which then can replace the function of the threads. In ideal cases the thread is immediately absorbed with a minimal tissue reaction. It is aimful to choose the suture material based on the wound healing properties and dynamics of the given tissue or organ. Doing so, we can select a suture material which keeps its tensile strength for the whole period of time needed. A question arises here: is the tissue reaction developing during the absorption of an absorbable suture material or the foreign body reaction which occurs due to a nonabsorbable suture material more harmful to the patient?

Two types of absorption are: enzymatic and hydrolysis. The enzymatic absorption is active and done by cellular elements. It is the characteristic of the natural suture materials which contain proteins. The results of it can be severe tissue reaction, activation of the inflammatory processes, formation of the microabscesses, and pathologic scar tissue. Its duration of absorption can not be defined and in different structures significantly different results can be obtained from the same suture material.

The hydrolysis is passive and done without participation of the cellular elements. It is the characteristic of the synthetic suture material. During hydrolysis the chemical and physical bonds located between the molecules of the suture material, become loose and the thread is disintegrated to such substances which are similar to the natural metabolites of the body and are lost from the body. The duration of the absorption of these suture materials can be estimated.

The advantages of the non-absorbable suture materials can be important when due to the properties of the tissue even after a long time there is no possibility for formation of a scar which can insure a real mechanical strength. Examples for this include: implantation of the cardiac prosthetic valves, implantation of the prostheses which replace the ligaments of the joint, and fixation of the vascular grafts. It is important to know that always there is a possibility for development of a severe fibrotic reaction around even the most modern and inert suture materials. This can be a bed for granulomas, microabscesses and rejection of the sutures.

Taken together, we can say that with some exceptions the synthetic, absorbable suture materials -which are absorbed by hydrolysis-, are preferred.

Table 3. Comparison of absorbable and non-absorbable suture materials

| | Absorbable | Nonabsorbable |
|---------------------|---|---|
| Advantage | Body disintegrates it, no foreign body remains behind No foreign body reaction | Permanent wound unifying |
| Disadvantage | Wound unifying time is limited | Foreign body remains behind and can lead to foreign body reaction, granuloma, microabscesses, fibrosis, rejection of the suture |

Table 4. Some important suture materials

| Trade name | Composition | Basic material | structure | Behaviour in body | use |
|----------------------|----------------------------|----------------|----------------|-------------------|---|
| Softcat plain | Sheep small intestine | Natural | Monofilament | Absorbable | Since 2000, it is forbidden to use the catgut sutures |
| Mersilk | Raw silk spun by silk worm | Natural | Braided | Nonabsorbable | It is not advisable any more |
| Linatrix | Linen | Natural | Braided | Nonabsorbable | For ligations |
| Dexon II. | Poliglicolic acid | Synthetic | Braided | Absorbable | Skin, subcutaneous tissue, muscles |
| Vicryl rapide coated | poliglactin | Synthetic | Coated braided | Absorbable | Skin (child) No need to remove the suture |
| PDS II. | Polidioxanone | Synthetic | Monofilament | Absorbable | Soft tissues, children, plastic and GIT surgeries |
| Maxon | Poliglicolic acid | Synthetic | Monofilament | Absorbable | Fascias and tendon sutures |
| Nurolon | Polyamide | Synthetic | Braided | Nonabsorbable | Soft tissue sutures, ligations |
| Safil | Poliglicolic acid | Synthetic | Braided | Absorbable | GIT surgeries, urology and OBG |
| Prolene | Polypropylene | Synthetic | Monofilament | Nonabsorbable | Cardiovascular and plastic surgeries |
| Steel | Stainless steel | Synthetic | Monofilament | Nonabsorbable | Closure of sternum |

Suture size

The USP (United States Pharmacopoeia) unit is frequently used to determine the diameter of the threads. The USP unit is grouping the suture materials according to their size. Based on this, the thinnest suture material is 11/0. Then, we have 10/0, 9/0, 8/0, 7/0, 6/0, 5/0, 4/0, 3/0, 2/0, 0, 1, 2, 3, 4, 5, 6, and 7 which is the thickest one. Next to the USP unit, the metric system is also accepted (especially in Europe). This is compatible with SI and it is also registered in the EP (European Pharmacopoeia). The metric system determines the thickness of the sutures in 1/10 mm. In Hungary the USP unit is used in practice.

Here we show some packed suture materials. We can get many important informations related to the suture and needle based on the international signs (Figure 45-47.)

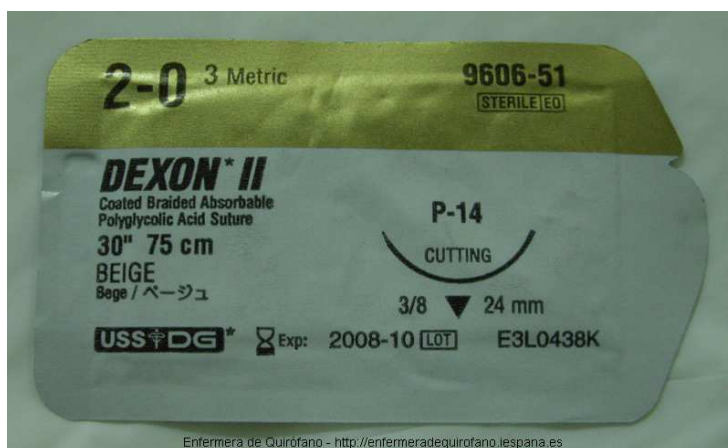


Figure 45. Trade name: DEXON II, Size: in USP system: 2-0 and in metric system: 3 metric, structure: coated braided, absorbable suture material, composition: Polyglycolic acid, length: 75 cm, needle: cutting; sized 3/8 circle; length: 24 mm; P type needle.

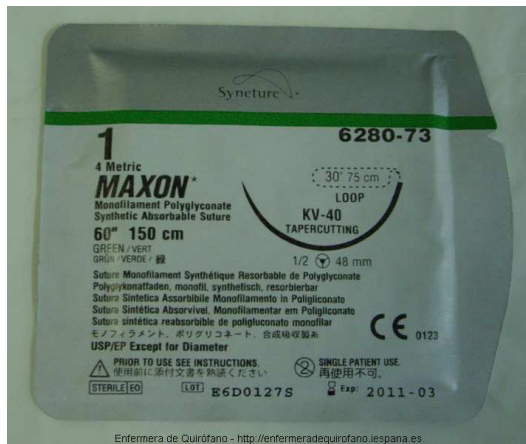


Figure 46. Trade name: MAXON, size: in USP system: 1 and in metric system: 4 metric, structure: synthetic; monofilament, absorbable suture material, composition of the green coloured one: Polyglyconate, length: 150 cm, needle: taper-cutting curved; sized 1/2 circle; length: 48 mm (loop suture material)

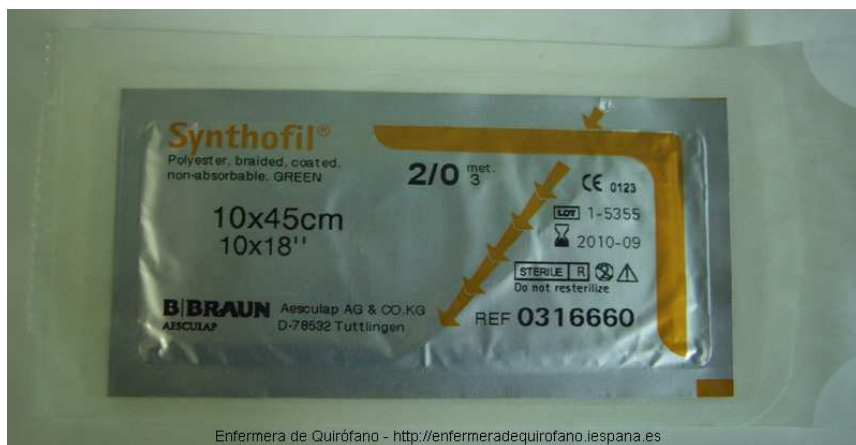

Figure 47. Trade name: Synthofil, size: in USP system 2/0 and in metric system 3 metric, structure: braided, nonabsorbable suture material, composition of the green coloured one: Polyester, 10 pieces each of them with a length of 45 cm, no needle inside the pack

4.3. Types of sutures

4.3.1. Interrupted sutures

Simple interrupted suture

This is frequently used to suture skin, fascia and muscles. After each stitch, a knot should be tied. All sutures must be under equal tension. The advantage is that the remaining sutures still ensure an appropriate closure and the wound will not open if one suture breaks or is removed. The disadvantage is that it is time-consuming since each individual suture must be knotted (Figure 48.).

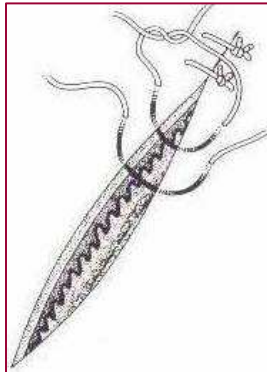


Figure 48. Simple interrupted suture

Vertical mattress suture (Donati or Vertical U-shaped suture)

It is a skin suture. It is a 2-row suture. It consists of a deep suture that involves the skin and the subcutaneous layer (this closes the wound) and of a superficial back stitch placed into the wound edge (this approximates the skin edges). The two stitches are in a vertical plane perpendicular to the wound line (Figure 49.).

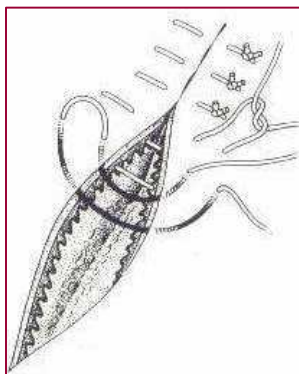


Fig 49. Vertical mattress suture

Allgöwer suture

It is a special form of vertical mattress suture: on one side of the wound, the thread does not come out from the skin, but runs intracutaneously. In this case, a thin scar is formed (Figure 50.).

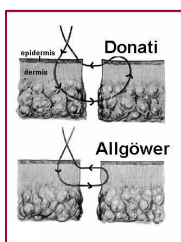


Figure 50. Allgöwer suture

Horizontal mattress suture (U-shaped suture)

This is a double suture: the back stitch is 1 cm from the first one, parallel to it in the same layer. Can be used in short skin wound (Figure 51.).




Figure 51. Horizontal mattress suture

4.3.2. Continuous sutures

Simple continuous suture

This can be applied to suture tissues without tension, the wall of inner organs, the stomach, the intestines and the mucosa (Figure 52.).

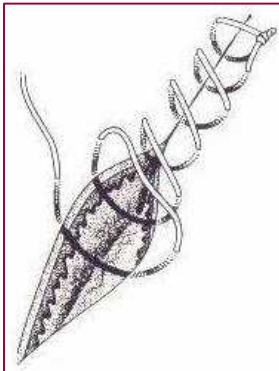
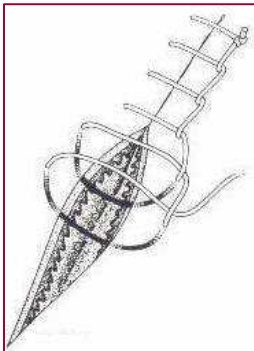


Figure 52. Simple continuous suture

Advantages: 1. It can be performed quickly, since a knot should be tied only at the beginning and the end of the suture (here, only a part of the thread is pulled through and the strands of the opposite sides are knotted). 2. The tension is distributed equally along the length of the suture. During suturing, the assistant should continuously hold and guide the thread to prevent it from becoming loose.

Locked continuous suture



Intracutaneous continuous suture

This runs in intracutaneous plane parallel to the skin surface; it enters the skin at the beginning and comes out at the end. It produces a fine scar. At both ends, the thread can be tied or taped to the skin (Figure 54.).




Figure 54. Intracutaneous continuous suture

Purse-string suture

The openings of the gastrointestinal tract (e.g. in appendectomy) are closed with this suture. An atraumatic needle and thread are used. It is a suture for a circular opening, running continuously around it. The wound edges are then inverted into the opening with dressing forceps and the threads are pulled and knotted (Figure 55.).

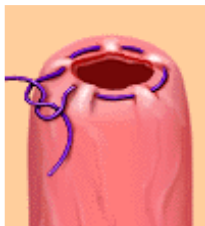

Figure 55. Purse-string suture

4.3.3. Removing sutures

The time of removal (usually within 3–14 days) depends on the location of the suture (sutures are removed later from a field which is under tension), the blood supply of the operative field (sutures can be removed earlier from an area that has good circulation) and the general condition of the patient. Sutures on the face can be removed after 3–5 days, those on the skin of the head and the abdominal wall after 7–10 days, those on the trunk and the joints after 10–14 days, those on the hand and arm after 10 days, and those on the leg and foot after 8–14 days.

Removing simple interrupted sutures

After careful disinfection of the wound, the suture is grasped and gently lifted up with a thumb forceps. The thread should be cut as close to the skin as possible so that no thread which was outside the skin should be pulled through the wound. In this way, infection of the wound can be avoided.

Removing continuous sutures

In the case of locked continuous sutures, the thread is cut between the knot -which is located at

one end- and skin and then the thread is removed. In continuous subcuticular sutures, one end of the suture is cut above the skin and the other end is pulled out in the direction of the wound.

Removing wound clips

Done with the Michel clip applicator and remover. The ring of one end of the clip is grasped with a tissue forceps, the edge of the remover is placed between the clip and the wound line, beneath the apex of the clip. The instrument is closed, the clip will open and the teeth of the clip will come out of the skin.

5. WOUNDS AND THE BASIC RULES OF HANDLING THEM BLEEDING, HEMOSTASIS, THE PROCESS OF WOUND HEALING

5.1. Wounds and the basic rules of their handling

Wound is a circumscribed injury which is due to an external force and can involve any tissue or organ. It can be mild, severe, or even lethal. As a result of wound, the liquid and element parts of the blood are lost and the protective function of the skin is disturbed. These result the microorganisms and the foreign bodies to enter into the body. The exposure of body cavities and internal organs means a further risk.

In simple wounds, skin, mucous membrane, subcutaneous tissue, superficial fascia, and the muscles (partially) can be injured (Figure 56.). This needs a simple wound management which can be done even by a nonspecialist. In the case of compound wounds beside those tissues which can be injured in a simple wound, there are injuries of muscles, tendons, vessels, nerves or bones. The joint space may become opened and if the body cavities are injured then there will be a possibility for injury of the internal organs as well. Management of such these wounds is done by a specialist and there is need for well-equipped institutes and a work team (consisting of surgeon, traumatologist, and anaesthesiologist).

The accidental wounds can be either open or closed. Wounds can result from mechanical, thermal or chemical forces and irradiation. The surgical wounds are the sign of the surgical incisions or interventions. They are usually produced in sterile circumstances and during a surgical intervention the surgeon close them layer by layer.

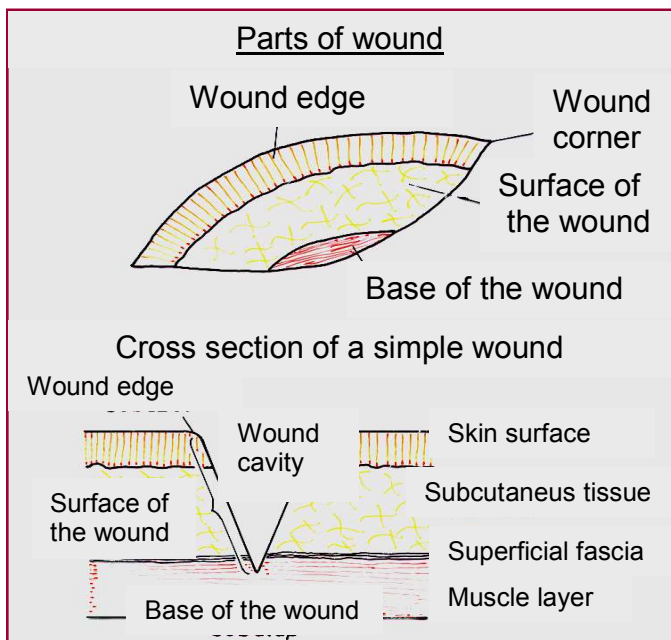


Figure 56. Simple wound

5.1.1. Classification of the accidental wounds

1. Classification based on the origin of the wound

Mechanical wounds

Punctured wound (vulnus punctum) is caused by a sharp pointed tool. It is misleading and sometimes seems to be negligible. Dangers: possibility for an anaerobic infection, there can be a possibility for injury of big vessels and nerves which are located deep to the wound (Figure 57.).

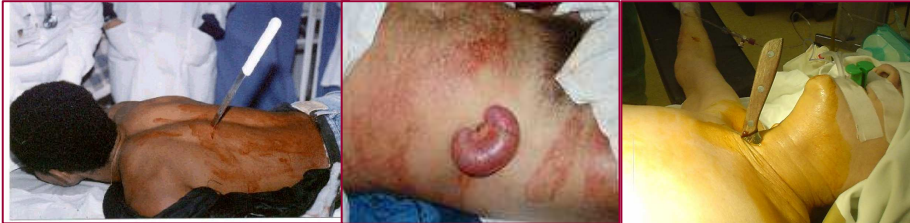

Figure 57. Punctured wounds

Incised wound (vulnus scissum): is caused by sharp objects; sharp wound edges are extending up to the base of the wound; the angles of the wound are narrow. All tissues are cut sharply and without any shattering. All surgical incisions belong to this type. It exhibits the best healing (Figure 58.).

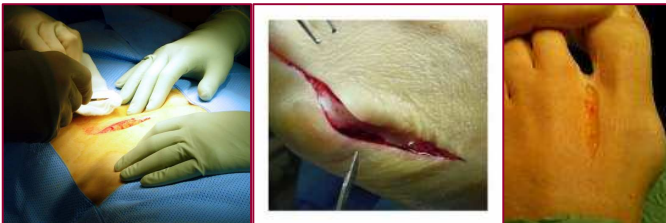

Figure 58. Incised wounds

Cut wound (vulnus caesum): is similar to an incised wound, but a blunt additional force also plays a role in its appearance. The degree of shattering is big in the cut tissues and the edges of the wound are uneven (Figure 59.).

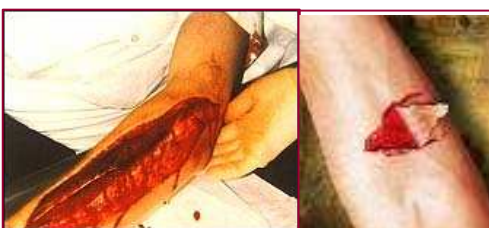

Figure 59. Cut wounds

Crush wound (vulnus contusum): is caused by a blunt force and can be either open or closed. The essence is: there is a pressure injury between the external force and the hard (bony) base. The edges are uneven and torn. The bleeding is negligible, but the pain is proportionately greater than would be expected from the size of the injury (termed wound stupor)(Figure 60.).

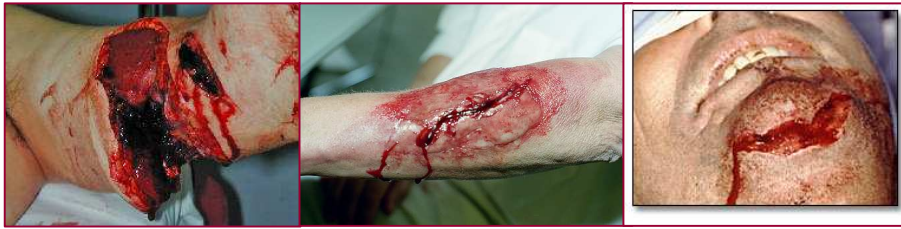

Figure 60. Crush wounds

Torn wound (vulnus lacerum): is caused by great tearing or pulling forces and can result in the incomplete amputation of certain body parts (Figure 61.).

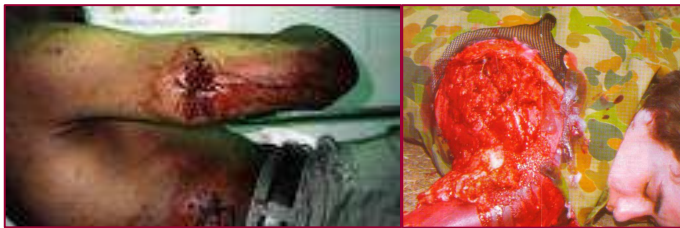

Figure 61. Torn wounds

Shot wound (vulnus sclopetarium): consists of an aperture, a slot tunnel and a possible output. A shot from a close distance is usually accompanied by some degree of burn injury at the aperture. Characteristic features are the incorporated foreign materials (e.g. textile fibers and bullets) and the altered injuries of the tissues locating in the course of the slot tunnel (Figure 62.).

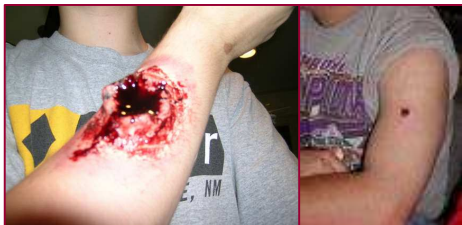

Figure 62. Shot Wounds

Bite wound (vulnus morsum) is a ragged wound with crushed tissue characterized by the shape of the biting teeth and the force of the bite. It is also accompanied by the features of torn wounds. There is a high risk of infection. It is produced by either animals or humans (Figure 63.).

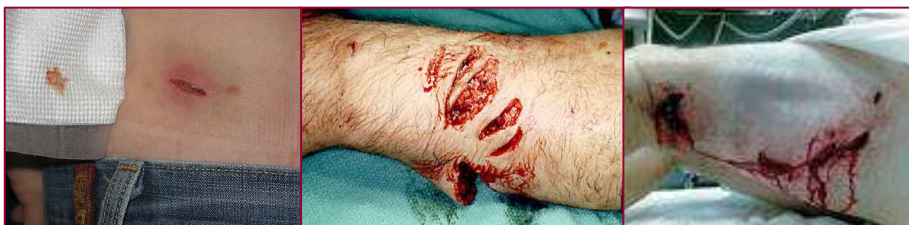

Figure 63. Bite wounds

Chemical wounds

Acid in a small concentration can irritate the skin or mucous membrane, while a large concentration of it leads to a coagulation necrosis. Treatment: similar to the burn injury.

Base leads to the colliquative necrosis. The connective tissue is loosened and the necrosis is extended deeply. Treatment: similar to the burn injury.

Wounds produced by radiation

The x-ray (depending to its dose) can lead to erythema and dermatitis. The later complications can be: fibrosis and ulcer (Figure 64.).

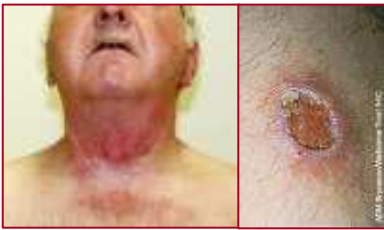

Figure 64. Postradiation dermatitis and radiation ulcer

2. Classification of the wounds according to bacterial contamination

Clean wounds (operation or sterile conditions): only the normally present skin bacteria are detectable with no signs of inflammation.

Clean-contaminated wounds: the contamination of clean wounds is endogenous or comes from the environment, the surgical team, or the patient's skin surrounding the wound. They include opening of the digestive, respiratory or urogenital tract.

Contaminated wounds (significant bacterial contamination): arise when an incision is performed acutely in a non-purulent area or in cases of a leakage from the gastrointestinal tract.

Dirty wounds: the contamination comes from an established infection. Examples include: residual nonviable tissues and chronic traumatic wounds.

3. Classification of the wounds depending on the time passed since the trauma

Acute (mechanical and other injuries):

- Fresh wound: treatment within 8 h.
- Old wound: ≥ 8 h after discontinuity of the skin.

Chronic (venous, arterial, diabetic and other ulcers, and skin or soft tissue defects):

- They do not heal within 4 weeks after the beginning of wound management.
- Without treatment, they do not heal within 8 weeks.

4. Classification of the wounds depending on the depth of injury

Grade I: superficial wounds: abrasion; only epidermis and dermis (up to the papillae) are involved.

Grade II: partial-thickness skin wounds: involves the whole thickness of the dermis (intact islands of the hair follicles and sweat glands).

Grade III: full-thickness skin wounds: skin and the subcutaneous tissue are involved (loss of tissue and gaping wound edges).

Grade IV: deep wounds or complex wounds (e.g. lacerations, or vessel and nerve injuries), or wounds of the bone or supporting structures, the opening of body cavities, or penetrating injuries of organs.

5.1.2. Management of the accidental wounds

Basic principles

All accidental wounds are considered as infected wounds. There is a need to remove the microorganisms and the nonviable tissues from the wound. An accidental wound should be transformed to a surgical wound.

Inspection

Examination of the wound under sterile conditions (cap, mask and gloves).

Anamnesis

- To clarify the circumstances of the injury. When did it happen? The faster we examine the patient, the less possibility exists for infection. Is there any accompanying disease which can effect on the healing process (e.g. DM, tumor)? Clarification of the circumstances of the injury can help us to judge about the danger of infection.

- To clarify the state of patient's vaccination against Tetanus. In the case of infected wound, to give human anti-tetanus Ig. The vaccination and registration are happening in the admitted traumatological ward.

- Prevention from rabies: in the case of a bite wound (name of vaccine: Rabipur, given at the time of injury and then at the 3th, 7th, 14th, 30th, and 90th days)

Diagnostic procedures

- To exclude the accompanying injuries.

- Examination of the circulation, sensory + motor functions, as well as bone.

Types of the wound management

Temporary wound management (first aid): aim to prevent the secondary infection.

– cleaning of the wound

– hemostasis

– covering

Final primary wound management:

surgical wound closure can be performed if maximum 12 hours is passed since the time of injury.

– cleaning,

– anesthesia,

– excision (< 6–8 h, exception: face, hand),

– sutures (in the case of puncture, bite, shot, and shattered wounds → situating sutures + drain)

Always the primary wound closure is performed in the case of injuries involving the:

– thoracic cavity,

– abdominal wall, and

– the dura matter.

The primary wound closure is contraindicated:

In the following cases, after clearing of the wound and washing it with physiologic saline solution cover it with a sterile bandage and put it in rest. Four to six days later, you can apply the delayed sutures.

– signs of inflammation,

– the wound is strongly contaminated,

– the removal of the foreign body was not successful,

– shattered wounds with blind spaces,

– injuries of persons with especial jobs (e.g. surgeon, butcher, veterinarian, pathologist), and

– bite, shot, and deep punctured wounds.

Need to do: cleaning + covering and after 3-8 days delayed primary wound closure.

In the management of the war injuries, we never do the primary wound closure.

- Such these injuries are considered to be infected with aerobic and anaerobic bacteria.
- The readiness of the injured person to fight against the infection is lost.
- Exceptions are: penetrating injuries of the skull, thorax, and abdomen.

Alternatives:

_delayed primary suture (3-8 days)

- to bring the edges of the wound close to each other with the help of adhesive tapes and later to perform the sutures
- situating sutures + drain
- early secondary wound closure (> 14 days)
- late secondary wound closure (4–6 weeks)
- plastic procedures

Primary delayed suture

If no signs of infection occur within 4–6 days, suturing (or situating suturing) is performed after excision of the wound edges. 3–8 days later: anesthesia + excision (refreshment of the wound edges) and suturing.

Early secondary wound closure

If following the first management of the wound, the excised wound -after inflammation and necrosis- starts to proliferate, then there is a need to refresh the wound edges. 2 weeks after the injury: anesthesia, excision (refreshment of the wound edges), suturing, and draining.

Late secondary wound closure

The proliferating former wound parts and scars should be excised. With greater defects, plastic surgery solutions should also be considered. 4–6 weeks after the injury: anesthesia, excision (of the secondarily healing scar), suturing, and draining.

5.1.3. Surgical wounds

2.1. Determinants of healing of surgical wounds

Preparation of the operating site, hygiene, shaving, disinfection and isolation are. The incision should be parallel to the Langer lines. The skin is stretched, the scalpel is held in a vertical position and the incision is performed until the subcutaneous layer is reached. It is important to be aware of the anatomical structures of the involved area. The muscle is separated along its fascia. The handling of bleeding is of importance.

Skin incision

The skin incision is made on a prepared (cleansed, draped) operative field with taking into consideration of vessels and nerves of the area. During the incision, the surgeon and the assistant stretch the skin. Usually a scalpel is used. The type of the scalpel depends on the site of the incision. The manner of holding the scalpel varies according to the use:

- for a long, straight incision or when there is a need to apply a bigger force, the scalpel is held like a fiddle bow.
- for the delicate, curved incision of fine structures, the scalpel is held like a pen.

The important requirements of the skin incision

- The length of the incision should be appropriate for safe surgery.
- Vessels and nerves should not be damaged.
- The skin edges should be smooth.
- The incision is made perpendicularly to the skin with a single definite cut (failed attempts result in ragged edges and prevent wound healing).
- The direction of the incision depends on the location of the organ being operated on.
- The skin is incised parallel to the Langer lines (better wound healing and less scar formation).
- The incision is usually directed toward the operator and from left to right (right-handed person).
- The depth of the incision must be the same throughout the whole length. At the beginning, the tip of the scalpel is inserted perpendicularly into the skin, the cut is made an angle of 45° with the blade of the scalpel (not with the tip!), and the incision is completed with the scalpel held perpendicularly.
- The skin scalpel is discarded into the container after the skin incision. In the deeper layers, another scalpel is used.

Main types of skin incisions based on body region

Neck: Kocher's transverse incision at the base of the neck (thyroid gland),

Thorax: sternotomy, thoracotomy,

Abdomen: subcostal (gallbladder or spleen), median/paramedian laparotomy (this may be upper or lower relative to the umbilicus), transrectal/pararectal/transverse laparotomies, Pfannenstiel suprapubic incision (bladder, uterus or ovaries), McBurney incision (appendectomy), inguinal incisions (hernia).

Closure and dressing of the surgical wounds

Fascia and subcutaneous layer: interrupted stitches. The fat must not be sutured (fat necrosis). Skin: tissue-sparing technique, with accurate approximation of the skin edges. Tension and ischemia of the skin edges are to be avoided. Simple interrupted stitch, Donati vertical mattress suture, Allgöwer stitch, continuous intracutaneous (or subcuticular) suture, Steri-Strips, clips and tissue glues may be applied to close the wound. Dressing: sterile, moist, antibiotic-containing, non-allergic and non-adhesive dressings. Holding the dressing: adhesive tapes, elastic bandages, and stretchable meshes. The dressing is removed on the 1st postoperative day, and daily in cases of infection.

5.1.4. Process of wound healing, types of it, and its risk factors

Hemostasis–inflammation (days 0-2)

Signs of inflammation (heat, pain, redness, and swelling) are present. The wound fills with blood clot and platelet aggregates, and fibrin production develops. The blood flow is increased, and macrophage and leukocyte mediators are released. Removal of bacterial components.

Granulation–proliferation (days 3-7)

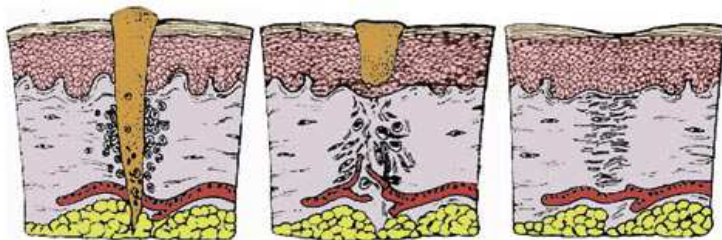
Characterized by the formation of granulation tissue and fibroblasts. Collagen and elastic fibers protect against the infection and they provide a suitable medium for re-epithelization. The healthy sprout is red and does not bleed. Expressed angiogenesis and the connections between the loose extracellular matrix (ECM) and fibronectin are characteristic.

Remodeling (lasting for months from day 8)

Maturation = ECM remodeling, and continuous collagen deposition. The scar is characterized by intensive strand formation; the vascularity is reduced and becomes brighter. The ECM is loose and relatively weak (20% of the final strength after 3 weeks). The fibers contract and become smaller and stronger. This contraction can cause a reduction in joint functions. This is pronounced for a year, but remodeling continues for an indefinite time. The final strength of the wound is around 70-80% of that of uninjured tissue.

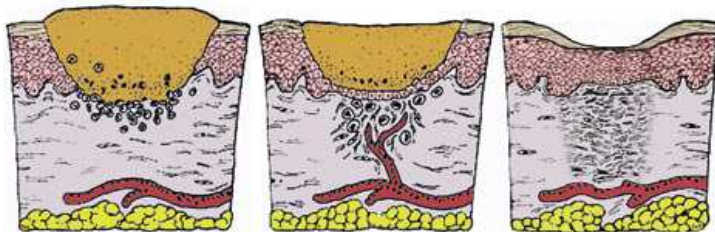
Types of wound healing

1. The scheme of *sanatio per primam intentionem* ("p.p. healing").



According to Galen: "the major aim" of a doctor is the gap-free healing of wounds.

2. The scheme of *sanatio per secundam intentionem*. The tissue loss is compensated by a granulation tissue "according to the second potential goal of the doctor". Due to the abacterial or purulent inflammation, the wound is filled with connective tissue which transforms into scar tissue.



Factors influencing wound repair

Some factors influence the process of wound healing. Among drugs: glucocorticoids inhibit fibroblast activity, protein synthesis and immune responses. Some antibiotics inhibit collagen biosynthesis. Cytostatic agents slow down metabolic processes. Anti-inflammatory agents reduce hyperemia and the blood supply to the wound. General condition, nutrition, protein level, vitamins B, C and K, and trace elements (Zn and Mg) (malnutrition slows down the healing process). Diabetes mellitus: There is a risk of infection, dysfunctioning of the micro- and macrocirculation, and hyperglycemia can lead to the development of chronic wounds. Icterus (the accompanying liver dysfunction influences the wound healing); similarly anemia, tumorous conditions and bacterial (or other) infections can influence the process of wound healing.

5.1.5. Complications of wound healing

Early complications of wound healing

Seroma: The wound cavity is filled with serous fluid, lymph or blood. Signs: fluctuation, swelling, redness, tenderness and subfebrility. Treatment: sterile puncture and compression; if repeated, then use a suction drain. It is common after the breast operations.

Hematoma: Due to an inefficient control of bleeding, a short drainage time or anticoagulation therapy. The risk of infection is high. Signs: swelling, fluctuation, pain and redness. Treatment: in the early phase, sterile puncture; later, surgical exploration is required.

Wound disruption: The major types are: partial, superficial (dehiscence), and complete separation (disruption). First, the deeper layers are involved and finally the skin. Local causes: a surgical error (e.g. suturing the fascia with a continuous suture), increased intraabdominal pressure and wound infection. Treatment: in the operating room and under general anesthesia, we apply the U-shaped en masse sutures to relieve tension.

Superficial wound infection

1. A diffuse and superficially spreading inflammation located below the skin (e.g. erysipelas, lymphangitis which is caused by hemolytic streptococci). Treatment: resting position, antibiotic, and dermatological consultation.

2. Localized (circumscribed) infection (e.g. an abscess). It can happen anywhere (e.g. under the skin, between the muscles, subfascially, in the thorax; brain; or liver). Treatment: surgical exploration and drainage. There is always a need to think of a foreign body (corpus alienum, filum suppuratio); it can develop even years later (X-ray examination is always necessary!).

Deep wound infections

1. Diffuse infection (e.g. an anaerobic necrosis). Treatment: surgical exploration, open therapy, rinsing the wound with H₂O₂, and antibiotics.

2. Localized infection (e.g. empyema), inside the tissues or body cavities (e.g. pleural and joint cavities). Treatment: surgical exploration and drainage (Staphylococcus aureus!).

Mixed wound infection

1. Gangrene: necrotic tissues, putrid and anaerobic infection; a severe clinical picture. Treatment: aggressive surgical debridement and effective and specified (antibiotic) therapy.

2. Generalized reaction: bacteremia, pyaemia, and sepsis.

Prevention of the wound infection

Taking into consideration the general basic rules for handling and treating a wound, a thorough examination, preparation, taking care of asepsis, rapid decision and if needed an extended exploration, to apply atraumatic techniques, and correct handling of the bleeding.

Signs and treatment of the wound infection

Local signs: rubor, tumor, calor, dolor and functio laesa. General signs: a rapid sedimentation rate of the RBCs, leukocytosis, fever, shivering, depression.

General therapy: rest and steam bandage if necessary. In the event of aggravation of the symptoms, wound exploration is performed under local anesthesia, with surgical removal of pus, necrotic tissues or foreign material (tissue sample is taken for bacteriological examination), daily rinsing with 3% H₂O₂ solution (or with antiseptics, povidone-iodine: Betadine, Braunol), open wound management and daily wound toilette.

Late complications of the wound closure

Scar formation in the penetration channels, hypertrophic scar, keloid formation, necrosis, inflammatory infiltration, abscesses and foreign body-containing abscesses.

Hypertrophic scar

These develop in areas of thick chorium. They are composed of non-hyalinic collagen fibers and fibroblasts. They are confined to the incision line. Treatment: they regress spontaneously, starting 3-6 months after surgery, and fall back to the level of the skin in 1–2 years (Figure 65.).

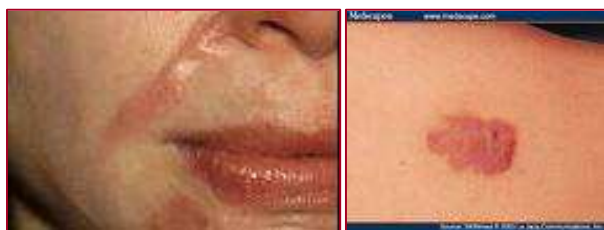

Figure 65. Hypertrophic scars

Keloid

These are of unknown etiology, they affect mostly African and Asian populations. They have well-defined edges, with pinkish-brown, emerging, tough structures, which result from the over-proliferation of collagen fibers in the subcutaneous tissue of the skin. They particularly affect scars on the presternal and deltoid areas and ears (Figure 66.). They are characterized with subjective complains (e.g. pain, itching sensation and aesthetic problems) and constant development. Treatment: intralesional corticosteroid+local anesthetic injections, postoperative radiation therapy. Prevention: with application of an atraumatic surgical technique.

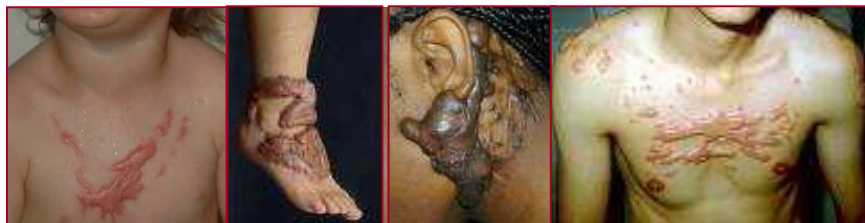

Figure 66. Keloids

5.2 Bleeding and hemostasis

5.2.1 Hemostasis

This is a natural, life-saving defense mechanism which has three main components: 1. vascular (vasoconstriction), 2. platelet, and 3. clotting. All of these inhibit or decrease bleeding from the vessels. During injury (e.g. a surgical incision), the endothelial damage exposes matrix proteins and collagen. Following this, the platelets clump and adhere to connective tissue at the cut site (adhesion). The platelets then release adenosine diphosphate (ADP), epinephrine, thromboxane A_2 , and serotonin (release). The binding sites for fibrinogen appear on the platelet membrane and fibrinogen becomes involved in platelet-platelet adhesion (aggregation). ADP and thrombin cause further platelet activation. In this way, the primary thrombus is formed. The clotting cascade is

also activated and with catalytic action of thrombin fibrin is produced from fibrinogen. Loss of the circulating blood is termed hemorrhage. This can be acute or chronic, primary or secondary. The causes of a secondary hemorrhage can be: infected wounds, inadequate primary wound care, inadequate or traumatic dressings, or necrosis of the vessel wall (e.g. compression, drain, etc.).

Anatomical bleeding

It is originating from a cut or injured bigger vessel. Arterial bleeding is bright red and pulsating with the cardiac function. The volume loss depends on the size of the artery. Venous bleeding is often a continuous flow of dark red blood with lower intensity. The amount of the lost blood and the danger of bleeding are more. If large veins are injured, there will be a possibility for the air embolism!

Diffuse bleeding

Origin: oozing from denuded or cut surfaces. The continuous loss of blood from oozing can become serious if it remains uncontrolled. Capillary bleeding: a tamponade with dry or wet (warm saline) towels is used to stop oozing. It is important to apply a continuous pressure because wiping the wound can remove the already-formed thrombi from the end of the capillaries. Parenchymal bleeding: absorbable sutures or gelatin are used. Minor bleeding during skin incision can be controlled by compression of the skin edges with towels.

Classification of bleeding

The patient destiny is determined by the volume of the lost blood and time passed since the bleeding was started. The severity of the bleeding depends on the volume of lost blood/time ratio. The value of this ratio depends on the size of the injured vessel, blood pressure, and the resistances of the surrounding tissues. The clinical outcomes are: bleeding to death, hemorrhagic shock, functional disturbances due to compression (cardiac tamponade, cerebral hemorrhage, breathlessness), anemia, and so on. To assess hemorrhage, the patient's mean blood volume must be known (males have ≈ 70 ml/kg (7% of the body weight), while females have ≈ 65 ml/kg. We classify the bleeding based on its severity.

| | Class I | Class II | Class III | Class IV |
|-----------------------|----------------------|----------------------|-----------------------------|-----------------------------|
| Blood loss[ml] | 0–750 | 750–1500 | 1500–2000 | >2000 |
| Mean blood volume [%] | 15 % | 15–30 % | 30–40 % | 40–50 % |
| HR | < 100 | > 100 | > 120 | > 140 |
| MAP | Normal | Normal | Decreased | Decreased |
| RR | 14–20 | 20–30 | 30–35 | > 35 |
| Capillary refill | Normal | Slight delay | > 2 sec | No filling |
| Skin | Pink, cold | Pale, cold | Pale, cold, moist | Mottled |
| Urine | > 30 ml/h | 20–30 ml/h | 5–15 ml/h | < 5 ml/h |
| Behavior | Slight anxiety | Mild anxiety | Anxious, confused | Lethargic, confused |
| Fluid therapy | No fluid/crystalloid | Crystalloid, colloid | Crystalloid, colloid, blood | Crystalloid, colloid, blood |

5.2.2. Direction of hemorrhage

Clinically, bleeding can be external (e.g. trauma, or a surgical incision resulting in visible hemorrhage) or internal (e.g. urinary tract: hematuria, respiratory tract: hemoptoa, GIT: hematochezia or melena). The latter can be directed toward body cavities (intracranial hemorrhage, hemothorax, hemascos, hemopericardium, and hemarthros), or among tissues (e.g. hematoma and suffusion). Bleeding can be classified according to the time of surgical interventions: it can be preoperative, intraoperative or postoperative.

Preoperative hemorrhage

Bleeding outside the hospital (see traumatology and anesthesiology). Prehospital care for hemorrhagic injuries includes: maintenance of the airways; ventilation and circulation, the control of an accessible hemorrhage with bandages; direct pressure and tourniquets (these methods have not changed greatly during 2000 years), and the treatment of possible shock with i.v. fluids.

Intraoperative hemorrhage

This can be anatomical and diffuse. Risk factors include drugs used in clotting disorders to reduce clotting (anticoagulants, antiplatelet drugs and thrombolytics), cirrhosis and liver dysfunction (clotting factors deficiency), uremia, hereditary coagulation disorders and sepsis. The main factors influencing intraoperative blood loss:

1. The attitude of the surgeon, his/her training and experience
 2. Planning of surgery - selecting the simplest technique-
 3. The optimal size of the surgical team. Meticulous attention to bleeding points - skillness of surgeon + proper use of diathermy, laser devices, tissue glues, and minimal invasive techniques-
 4. Posture - the level of the operative site should be a little above the level of the heart (e.g. the Trendelenburg position for lower limb, pelvic and abdominal procedures; and the reverse Trendelenburg position for head and neck surgery)-
 5. The size of the bleeding vessels.
 6. The pressure in the vessels.
 7. Hemostasis: the diameter of bleeding vessels decreases spontaneously due to vasoconstriction (more pronounced in arterioles than in venules).
 8. To handle the bleeding from arterioles is easier ("surgical") than that from the diffuse veins
- Anesthesia (!): Intraoperative bleeding depends much more on the B.P. rather than on the CO; the BP can be maintained at an optimally low level by the anesthesiologist. Various anesthetic techniques are applied to minimize preoperative blood loss:
- If adequate planes of anesthesia and analgesia are ensured, hypertension and tachycardia due to sympathetic overactivity can be avoided
 - Controlled anesthesia (increase in intratracheal pressure → increase in CVP → increase in PCO₂ → increase in B.P.)
 - Regional anesthesia (epidural or spinal): where appropriate can leads to 45% reduction in blood loss (sympathicolysis leads to a lower MAP, and spontaneous breathing to a lower CVP)
 - With use of the controlled hypotension
 - With proper drug therapy of the hypertensive patients

Postoperative bleeding

Causes: Ineffective local hemostasis, a complication of blood transfusion, a previously undetected hemostatic defect, consumptive coagulopathy, or fibrinolysis (a prostate, pancreas or liver operation). Causes of postoperative bleeding starting immediately after the operation:

- an unligated bleeding vessel;
- a hematologic problem arising as a result of the operation.

Therapy

- If the circulation is unstable, immediate reoperation is essential!
- Action to be taken if the circulation is stable:
 - reassessment of the history and medication given,
 - checking the body temperature; if it is low, the patient should be warmed,
 - laboratory coagulation tests.

5.2.3. Local and general signs and symptoms of bleeding

Local:

Visible signs: hematoma, suffusion, ecchymosis

- Compression[(e.g. breathlessness (pleural cavity, neck)]
- Constriction/compression:
 - Cardiac insufficiency (pericardium)
 - Increase in ICP (skull)
 - compartment syndrome (between muscles)
- Functional disturbances: hyperperistalsis (GIT bleeding), intestinal paralysis (retroperitoneal hematoma)

General signs: pale skin and mucous membrane, cyanosis, decreased B.P. and tachycardia, difficulty in breathing, sweating, body temperature is decreased, unconsciousness, cardiac and respiratory standstill, laboratory disorders, and signs and symptoms of shock (see later).

5.3. Surgical hemostasis

The aim of local hemostasis is to prevent the flow of blood from the incised or transected vessels. Bleeding which appears in the surgical territory makes the orientation difficult. It is one of the most dangerous complications of the surgery and the biggest obstacle to wound healing. These give the reasons to perform a proper intraoperative hemostasis. Methods are: 1. mechanical, 2. thermal, or 3. chemical.

5.3.1. Mechanical methods – temporary and final interventions

Digital pressure

When possible, direct pressure is combined with elevation of the bleeding site above the level of the heart. Applied over a proximal arterial pressure point. Intraoperative maneuvers [e.g. the *Pringle (Báron)* maneuver: compression of the vessels at the porta hepatis, in Hungary it was first applied by Sándor Báron in 1910]

Tourniquet

There is no completely safe tourniquet duration. In most cases, a tourniquet can be left in place for 2 hours without causing permanent nerve or muscle damage. A tourniquet is commonly used in hand surgery to produce a bloodless operative field.

Ligation

Artery forceps (Péan, Kocher, mosquito, etc.): this is the most commonly used method of hemostasis in surgery. The source of the bleeding should be grasped by a hemostat with minimal

inclusion of the neighboring tissues. This intervention (requiring the harmonized movements of the operator and the assistant) consists of three phases: soaking, clamping and ligation. First, the assistant applies only a pressure with the sponge and soaks up the blood (so, he does not cause a temporary vasoconstriction). The operator grasps the bleeding vessel with a Péan. The tip of the Péan should always face the person who will do the ligation. The scrub nurse gives the thread while she is keeping the two ends of it stretched. The thread used for ligation should be as thin as possible. After applying the first basic knot, the assistant releases the Péan but the surgeon stretches the thread further. After the 2nd knot, the operator cuts the thread as follows: the scissors are slid down to the knot and rotated a quarter turn. The least possible amount of the thread should stay in the wound (foreign body!). It is not advisable to use a ligation directly beneath the skin because it disturbs the healing process of the wound.

Suturing

Transverse, transfixing, "figure of 8" stitch (*sutura circumvoluta*). In cases of large-caliber vessels or diffuse bleeding, non-absorbable (e.g. silk, polyethylene or wire) and absorbable (e.g. catgut, polyglycolic acid (Dexon) or polyglactic (Vicryl) suture materials can be used. A double stitch (suture twice) is applied under the bleeding tissue to form an "8" shaped loop and the knot is then tied.

Preventive hemostasis (planned hemostasis)

It happens with ligatures. In the operating field, the vessel should be clamped with two Péans, the part of the vessel located between them is cut, and the two ends of the vessels should be tied separately. Deschamp needle and the Payr probe can be used for the same purpose.

Clips

Clips are metal or plastic. Applied with the help of disposable or non-disposable devices.

Bone wax

This is a sterile mixture of beeswax, almond oil and salicylic acid. It adheres readily to the bloody bone surfaces, thereby achieving local hemostasis of the bone. For example it is used to stop bleeding after cutting the sternum.

Expedients

Suction, drainage (Hemovac, Jackson-Pratt, etc.) to remove body fluids and air. This facilitates the emptying of dead spaces, improves tissue regeneration, and blocks the development of edema and hematoma.

Other devices or mechanical methods for handling bleeding

- Rubber bands for digits
- Esmarch bandage
- Penrose drain
- Vessel loops
- Pneumatic tourniquets
- Pressure dressings, packing (compression), tamponades, and sand bag

5.3.2. Thermal methods

Low temperature – hypothermia

Hypothermia (a hypothermia blanket, ice, cold solutions for stomach bleeding)

Cryosurgery: -20 to -180 °C cryogenic heat. Its mechanism:

- dehydration and denaturation of fatty tissue
- decreases the cellular metabolism/O₂ demand
- leads to vasoconstriction.

Heat (high temperature)

It based on protein denaturation.

Electrosurgery

- In Paquelin (Claude André Paquelin (1836-1905), French surgeon) electrocauterization (which stops bleeding by “burning” the bleeding vessels), the tissue is not part of the circuit. In diathermy, the patient is in the circuit. Electrical current incises/excises or destroys the tissue. The area is automatically sterilized and burned.

- Essence: hemostasis + an aseptic technique

- Parts of the electrosurgical unit: generator, cable and neutral (indifferent) electrode, parts which are connecting to the wires: knife, needle, loop, blade. The effect depends on the current intensity and wave-form used. Coagulation is produced by interrupted (damped) pulses of current (50–100/s) and a square wave-form. Cutting is produced by continuous (undamped) current and a sinus wave-form.

- The contemporary generators are working in an alternative manner [e.g. the surgeon regulates the cutting or coagulating functions. With the same electrode he can coagulate (at higher voltages) and cut (at lower voltages)]. The diathermy is not suitable for skin incision because it leads to burning injury of the skin. We use it only for deeper tissues.

Monopolar diathermy

Only one (the active) electrode is connected to the cutting/coagulating device. The electric current is passing through the patient between this active electrode and the indifferent (neutral) electrode which is located out of the surgical territory and touching a large skin surface. This electrode is placed at the time of positioning the patient on operating table.

Bipolar diathermy

In bipolar diathermy, two electrodes are combined in the instrument (e.g. forceps), and the current passes between the tips and not through the patient.

Local effectrosurgery

Electrocoagulation: a needle or disc touches the tissue directly, and burns the tissue (a grayish discharge). The tissues are expelled after 5-15 days. Use: bleeding coagulation.

Electrofulguration: lighting or spark: the needle does not touch the tissue directly (it is 1–2 mm away). Use: “Spray” function – control of diffuse bleeding.

Electrodesiccation: the needle is inserted into the tissues. Use: to destroy warts and polyps.

Electrosection: with a knife, blade or electrode. Use: excision or incision.

Laser surgery

Laser surgery is based on the emission of radiation by light amplification through a tube at a microscopic level. Use: coagulation and vaporization (carbon or steam) in delicate and fine tissues (eyes: retina detachment repair, brain, spinal cord, or gastrointestinal tract). The operator must wear safety goggles. Suction of the steam (CO₂) is necessary.

5.3.3. Hemostasis with chemical and biological methods

Characteristics: Easy handling, quick absorption, non-toxic, and local effects without systemic consequences. Expected consequences: vasoconstriction, coagulation and a hygroscopic effect.

Aethoxysclerol (polydocanol): This is not used for active coagulation. Main indications: small superficial skin varices (injection into the veins) and esophagus varix sclerotization (given to the proximity of the varix).

Absorbable gelatin: Gelfoam, Lyostypt or Spongostan: powder or compressed-pad form. Made from purified gelatin solution. Adsorption capacity: 45 times more than its own weight. Absorption takes place in 20-40 days.

Absorbable collagen: Collastat®: This is in the form of a hemostatic sponge, applied dry to the oozing or bleeding site. Its use is contraindicated when there is an infection or in areas where blood has pooled.

Microfibrillar collagen: Avitene®: This is a powder-like, absorbable material from a bovine source; it is applied dry. It stimulates the adhesion of platelets and the deposition of fibrin. It functions as a hemostatic agent only when applied directly to source of bleeding. It is applied to oozing surfaces, including bone and areas of bleeding difficult to reach.

Oxidized cellulose: Oxycel®, Surgicel®: made of cellulose, able to adsorb a large amount of blood, with blood make an artificial thrombus. They are absorbed in 7–30 days.

Oxytocin: This is a hormone produced by pituitary gland, but is also prepared synthetically. Use: e.g. bleeding from uterus.

Epinephrine: This hormone is secreted by the adrenal gland, is also prepared synthetically. It is a vasoconstrictor. It is rapidly dispersed and has a short duration of action.

Thrombin: This enzyme is extracted from the bovine blood. It combines rapidly with fibrinogen to form a clot. It is available in liquid (spray) and powder forms. It must not be allowed to enter large vessels. It is for topical use only and is never injected.

Novel hemostatic agents: Indications: External bleeding where the conventional pressure dressings fail. It is not used in those places where you can apply a tourniquet.

1. HemCon: It is available as a chitosan-based product, made from shrimp shell polysaccharide + vinegar. This is a firm 7x7 cm dressing that is sterile and individually packaged. It adheres to a bleeding wound, and exerts vasoconstrictive properties.

2. QuikClot: This granular zeolite absorbs fluid, acts as a selective sponge for water, dehydrates blood, has handling properties similar to those of sand, and can generate significant heat during the adsorption process.

6. OPERATION (ACUTE, ELECTIVE, PREPARATION OF THE PATIENT, SURGICAL EXPOSURES)

6.1. Preparations for an operation

”Salus aegroti suprema lex esto” = ”The well-being of the patient is the most important law.”

Aim: to perform the right operation, for the right reasons, on a right patient, and at a right time.

- From the financial and hygienic standpoints, the patient’s preoperative hospital stay should be as short as possible (Hospitalisation, iatrogenia, contamination)
- If it is possible, the patient should be admitted a day before operation or even at same day.

Careful examination of each patient individually is an important factor. The standpoint of ”Surgery is the aim!” should be neglected. We can think of increased surgical morbidity (and accompanying cardiovascular, hepatic, and renal diseases) as the age of the patient is increasing.

6.2. Surgical indications, contraindications and risks

Indications

Proper evaluation of the surgical disease and risks:

- Vital indications: These are involved in the case of life-saving procedures. The patient can be treated only with an operation (100% mortality without operation). Example: rupture of an abdominal aorta aneurysm
- Absolute indications: These are involved in urgent procedures. The disease can be treated exclusively with an operation. The time can be chosen between narrow limits. Example: mechanical ileus.
- Relative indications: These are factors in elective procedures, e.g. programmed operations. The disease can be treated with or without surgery. The time of surgery can be chosen. Example: hernia.

Contraindications

In the cases of vital and absolute indications: only in moribund patients.

In the case of relative indication: decompensated accompanying diseases, does the surgery improve the survival?

Surgical risks

Surgical risks = risks of surgery itself + anesthesiological risks. The preoperative examinations must answer the questions of both surgeon and anesthesiologist, allowing them to give their agreed opinion in writing.

1. Low-risk surgery: Minor operations belong in this group (e.g. inguinal hernia repair), where the expected blood loss is less than 200 ml.
2. Medium-risk surgery: Surgical interventions of medium severity can be classified here (the expected blood loss is less than 1000 ml), e.g. colon resection.
3. High-risk surgery: Extended abdominal and thoracic operations (e.g. liver and lung resections) fall into this category. The blood loss exceeds 1000 ml. The patient needs postoperative intensive care and treatment. The rates of postoperative morbidity and mortality are high.

The extent of the operation is a determinant:

Operations on body surfaces are running with the smallest risks. The risks of the operation increase if there is an opening of a body cavity. Operations done over the hollow organs are running with higher risks. The opening of many hollow organs is running with more risks. Operations in which 2 body cavities are opened at the same time are running with the highest risks.

Factors which increase the surgical risks:

- Acute surgery
- Duration > 2 hours
- > 65 years old
- Pregnancy
- Malignant diseases
- Malnutrition
- Alcohol consumption
- Smoking

- Organ alterations:
- Cardiorespiratory
 - Hypertention
 - Nervous system alterations
 - Diabetes mellitus
 - Chronic Uraemia
 - Cirrhosis
 - Susceptibility for infection
 - Immunosuppression
 - Thromboembolic predisposition

- Acute disturbances
 - hypovolaemia
 - dehydration
 - shock
- Acute inflammations
 - respiratory
 - urinary
 - gastrointestinal
 - sepsis
- Trombosis
- Acute organ insufficiencies:
 - Heart
 - Lung
 - Kidney
 - Liver
- Acute endocrine disorder

- Chronic disorders:
 - Hypovolaemia
 - Anaemia
- Chronic inflammations
 - Respiratory(bronchitis)
 - Urinary
 - Gastrointestinal (ulcer)
- Trombosis
- Allergia

- Organ insufficiencies
 - Heart
 - Lung
 - Kidney
 - Liver
- Endocrine disorders
- Immunological disorders
- Hemophilia

Pregnancy
- acute
- decrease

next to the pregnancy + surgical diseases
organs (respiration, circulation, metabolism)

- altered anatomical relations
- atypical symptoms
- possibility for foetal diseases

Menstruation

In the past, there was a tendency to avoid surgery on a menstruating woman due to increased psychic instability, possible increase in bleeding tendency, and increased hygienic demands seen during this period. Nowadays, the menstruation is not considered as an obstacle to do the operation.

Overfeeding as a factor increasing the surgical risk

- respiratory disturbance(usually restrictive): deteriorating the gas exchange, increased respiratory function
- decreased cardiac reservoirs
- difficulty with intubation (regurgitation)
- disturbances with wound healing
- thromboembolism

Immunological factors

Immunosuppression (transplanted patient), use of cytostatics (tumorous patient), AIDS and so on → increased possibility for infection, frequent wound healing disturbances.

Oncological patients' own problems

- chemotherapeutic agents
- radiotherapy (local inflammation)
- decreased function of the immune system
- paraneoplastic syndromes e.g. deep venous thrombosis

Increased age as a factor influencing the surgical risk-elderly patient

- elderly patient: age > 65 years old (the biological age is important and not the calendar age)
- to assess the expected benefits, risks, and the patient's survival
- to estimate the interactions between the drugs, used by patient for a long period of time and the necessary drugs which are given during the perioperative period
- cardiopulmonary deficiency is the cause of the death in most cases

Estimation of the surgical risks

It means to examine the followings:

- cardiovascular state,
- respiratory system,
- metabolic state,
- renal function,
- liver function,
- endocrine balance,
- homeostasis,
- immune system.

Examinations

- physical examination
- laboratory examination
- radiological examinations (US, CT, MRI, isotop, DSA, and so on)
- instrumental examination (endoscopy, biopsy, cytological examinations)

Heart and circulation:

- pulse, blood pressure
- ECG
- Echocardiography
- coronarography
- isotop

Increased cardiac risks:

- aortic stenosis, mitral stenosis
- dysrhythmia
- AMI: within 3 weeks→mortality: 25%
- AMI: within 6 weeks→mortality: 5%
- DM→silent ischemia 25%

Lung, breathing:

- Chest X-ray
- Respiratory function
- Blood gas analysis (preparation for the surgery: respiratory physiotherapy and inspiratory treatment)

Laboratory examinations:

- blood count
- blood group
- bleeding and clotting times
- liver function tests
- renal function tests
- examination of the metabolic processes
- fluid and electrolyte balance
- plasma protein level

Diet regulations

If it is possible, you should prevent the deterioration of the nutritional status of the patient during the processes of the preoperative examination and preparation. Sometimes, the nutritional therapy is a part of preoperative preparation. To have a safe general anesthesia, the patient should avoid eating (fasting 6 hours prior to surgery).

Preoperative nutritional therapy

First, you should consider the natural oral feeding. If it is not possible, then the nasogastric, duodenal or jejunal tubes are the most appropriate ways of feeding. The parenteral feeding is done through the peripheral or central venous catheters. The burned, tumorous, polytraumatized, and septic patients need the highest amount of energy.

Slag deprivation

- Diet: liquids for 2-3 days or a low-residue diet
- Enema: In the case of major abdominal surgeries (or those operations which involve the intestinal system), there is a need to make the intestinal tract empty.
- to make the stomach empty: In the case of pyloric stenosis, the nasogastric tube can remove the gastric contents and also lead to the gastric lavage(antibiotic).

Urinary catheter

It is needed in the case of long-lasting operations which are running with loss of a large amount of fluids.

Thrombosis prophylaxis

- Drugs:

- Heparin derivatives: Na-heparin, Ca-heparin, low molecular weight heparins
- Platelet aggregation inhibitors (e.g. Aspirin and Colfarit)
- Coumarin derivatives (e.g. Syncumar)

- Physical:

- early mobilization
- compression (elastic bandages)
- bed-side bicycle
- keeping the lower extremities at a high level

Psychic preparation

That is natural for the patient to fear of the operation and its unwanted consequences. The surgeon should deal with the patient's psychic state. He/she should carefully evaluate the indications and contraindications and choose the best possible intervention.

Legal aspects of the operations

- informing the patient (tumorous patients!)
- patient's written consent (this should also include those decisions which may be made by the surgeon intraoperatively).
- in the case of children, the parents or the legal representative should give the informed written consent.

6.3 Surgical approaches

6.3.1. Laparotomy on the anterior abdominal wall

The direction of the incision can be: vertical, transverse, or oblique.

Vertical incisions:

- upper, lower, middle, or total median laparotomy
- paramedian laparotomy
- vertical transrectal laparotomy
- pararectal laparotomy

Transverse incisions:

- horizontal transrectal laparotomy

- Pfannenstiel incision

Oblique incisions:

- McBurney-incision
- inguinal transmuscular laparotomy
- paracostal laparotomy (Kocher incision)
- subcostal laparotomy

Vertical incisions

Upper median laparotomy

The incision is made from xyphoid process to the umbilicus. Advantages: insures a quick and wide exposure, quickly and easily can be elongated and closed. Disadvantages: the fibrous tissue of the white line (linea alba) is cut and the sutures are upon tensions at both sides

which can be a cause for a later postoperative hernia (Figure 67. A).

Lower median laparotomy

The incision is made from umbilicus to symphysis pubis. The advantages and disadvantages are the same as those for an upper median laparotomy. About 2/3 of sterile wound disruption happens following such a this incision (Figure 67. B).

Middle median laparotomy

An 8-10 cm long incision. Half of it is located above and the other half below the umbilicus. At the umbilicus the incision is curved towards the left side. Advantage: from a small incision we can inspect both the upper and the lower part of the abdominal cavity.

Total median laparotomy

The incision is made from xyphoid process to the syphysis pubis. It gives an excellent exposure but injures the statistic of the abdominal wall significantly. The patient is predisposed to the postoperative wound disruption. It also makes the postoperative coughing difficult, increases the danger of pneumonia, and can cause constipation. This incision is generally used in the case of extended abdominal operations (Figure 67. A+B).

Paramedian laparotomy

It is generally used only above the umbilicus. About 2 cm right (an parallel) to the midline cut the skin, subcutaneous tissue and the anterior leaflet of the rectus sheath. The rectus muscle is retracted. Following this, the posterior rectus sheath is also cut. The later scar will be strong and the possibilty for development of a henia is rare (Figure 67. C).

Transrectal laparotomy

About 2-3 cm right to the midline cut the skin, subcutaneous tissue, and the anterior leaflet of the rectus sheath. Then, separate the fibers of the rectus muscle from each other bluntly to be able to cut the posterior leaflet of the rectus sheath (together with transversalis fascia and the parietal peritoneum)(Figure 67. D).

Pararectal laparotomy

A vertical incision is parallel to the rectus muscle. Due to the denervation of the muscles the abdominal wall becomes significantly weakened. It is danger for development of a huge hernia. It is not advisable (Figure 67. E).

Lateral transmuscular laparotomy

The incision is made starting from a point located 2-3 cm lateral to the external edge of the rectus muscle. The longest incision of such starts at the lower edge of the 10 th rib and runs till the level of the anterior sup. ilac spine. The” pararectal” and ”an incision made alongside the semilunar line of Spiegel” are not the ideal incisions because they weaken the abdominal wall significantly. They are not advisable (Figure 67. F).

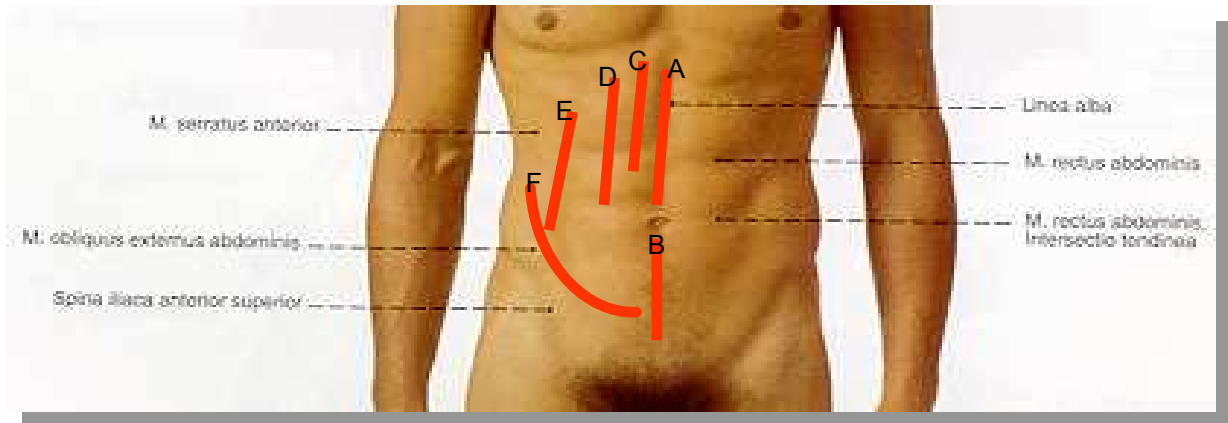


Figure 67. Vertical laparotomies

A. Upper median laparotomy, B. Lower median laparotomy, A+B Total median laparotomy, C. Paramedian laparotomy, D. Transrectal laparotomy, E. Pararectal laparotomy, F. lateral transmuscular laparotomy

Transverse and oblique laparotomies

They cause less injury to the nerves of the abdominal wall muscles. In this way, the possibilities for postoperative sterile wound disruption and later hernia are less.

Upper transverse laparotomy

The incision is made at the area between the xyphoid proc. and the umbilicus, starting from one external edge of the rectus muscle and ending at its other edge (It is at the border line between the middle and lower 2/3) (Figure 68. A). This incision can be made larger by elongating it at both of its lateral sides (even up to the middle axillary lines). This incision rarely injures the abdominal wall muscles. The innervations of these muscles are not injured and the wound heals with development of a strong scar. In upper abdominal surgeries we can combine the upper median incision with a transverse incision. Such this incision is called: the Mercedes-Benz incision.

Lower transverse laparotomy

This a mild concave incision a few centimeter below the umbilicus (Figure 68. B). One or both rectus muscles are cut. Sometimes, we only cut the rectus sheaths and do not incise the muscle itself. The incision can be elongated laterally.

Paracostal laparotomy

A curved incision started from xyphoid proc. to the lateral side of the abdominal wall. It is located 2-3 cm below and parallel with the costal margins (Figure 68. C). The possibility for development of a postoperative hernia is high. On the left side, this incision is helpful in performing a splenectomy. On right side it can be used to perform an open cholecystectomy. Nowadays, with application of the laparoscopic cholecystectomy we can avoid the postoperative pain and complications of such this incision!

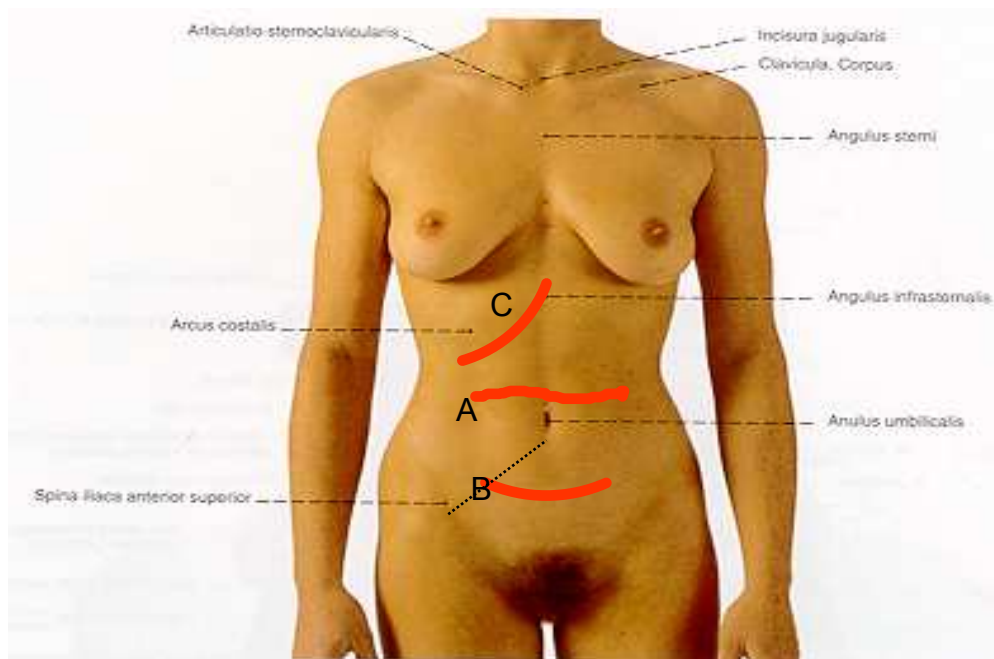


Figure 68. Transverse and oblique laparotomies

A. Upper transverse laparotomy, B. Lower transverse laparotomy, C. Paracostal laparotomy

Muscle-splitting incisions

In these types of incisions the fibers of the abdominal wall muscles are not cut but separated from each other alongside their courses. Advantage: the possibility for developments of postoperative hernia is rare. Disadvantage: it gives a limited exposure and is helpful only in the case of a sure diagnosis.

Lower median muscle-splitting incision (Pfannenstie incision)

A transverse incision about 2-3 finger breadths above the symphysis pubis and between the two external edges of the rectus muscles. The anterior rectus sheaths are cut and the rectus muscles are retracted bluntly. It is used mainly in OBG (Figure 69. A).

Upper lateral muscle-splitting incision

It is used exclusively in the newborn babies for the purpose of pyloromyotomy. Performed on the right side (Figure 69. B).

Lower lateral muscle-splitting incision ((McBurney incision)

One of the most common types of incisions they are. A 4-6 cm long incision made at the middle and outer 1/3 of an imaginary line which connects the right ant. sup. iliac spine to the umbilicus. 1/3 of this incision is located above and 2/3 of it below this imaginary line. Starting with separation of the fibers of the ext. oblique muscle we finally explore the appendix (Figure 69. C).

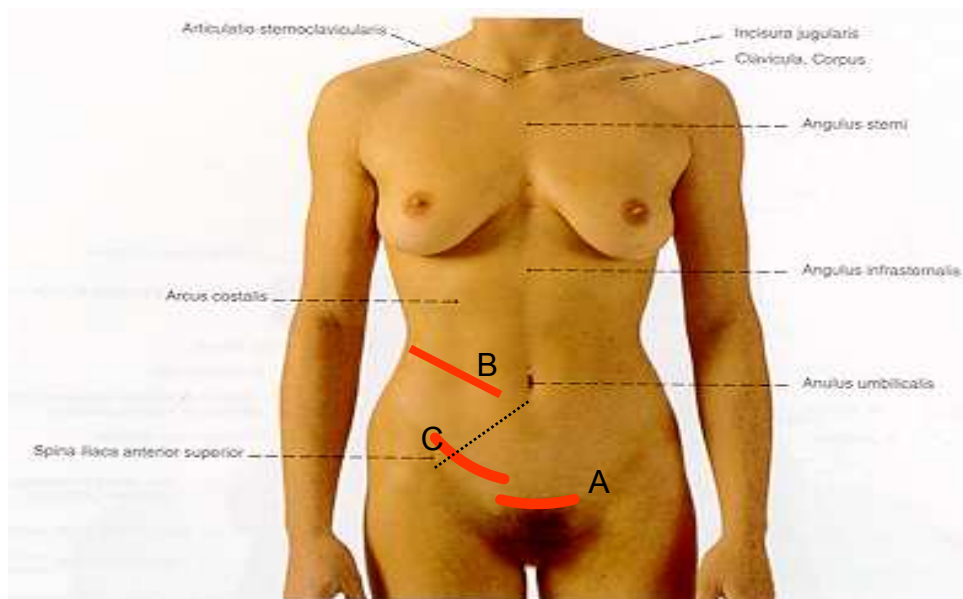


Figure 69. Muscle-splitting incisions

A. Pfannenstiel incision, B. Upper lateral muscle-splitting incision, C. McBurney incision

6.3.2. Laparotomy on the posterior abdominal wall

Oblique posterior approach (Bergmann-Israel incision)

Starting from the lower edge of the 12th rib we go towards the ant. sup. iliac spine and then parallel with the Poupart lig. we end our incision at the ant. abdominal wall. To have a better exposure, it is also necessary to resect the 12th rib subperiosteally.

Vertical posterior approach

It is a rarely used incision which is made alongside the external edge of the deep back muscles.

6.3.3. Thoracolaparotomy

In the case of big tumors of the liver, tumors of the kidney, possibly the total gastrectomy, operations done around the cardia region, and oesophageal tumors, when there is a need to open the thoracic and the abdominal cavities simultaneously, we apply this incision. It is an upper transrectal or an upper transverse laparotomy which is running alongside the 7th intercostal space.

6.3.4. Skin incisions and the positions of the trocars in laparoscopic surgeries

Within the last 2 decades, the most significant development in surgery was the appearance of the laparoscopic surgery. During the conventional open surgery the surgeon has the possibility to palpate the abdominal cavity and exclude the presence of other diseases. Disadvantages of this type of approach are: long hospital stay and rehabilitation period, returning to work after a long period of time, decreased ability to perform the customary work, and possibility for the postoperative hernia.

In laparoscopic approach we can inspect the abdominal cavity only visually. The degree of postoperative pain and the duration of hospitalization are significantly decreased. The recovery is faster and patient can go to work even a few days after operation. The most commonly performed laparoscopic surgery is the laparoscopic cholecystectomy. The Figure 70. shows the position of the trocars.

The right lower abdominal cavity can also be approached by laparoscopic instruments which is primarily important from standpoint of differential diagnoses. Nowadays, more and more appendectomies are done by this method which consequence is absence of usual appendectomy scar (Figure 71.). In the case of recurrent lower abdominal pain this can cause a dilemma for uncared practioners.

The minilaparotomy incisions needed in hand-assisted laparoscopic surgeries are more frequently located at the midline.

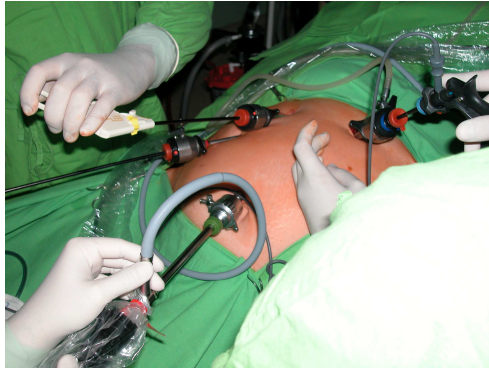


Figure 70. Trocars placed during a laparoscopic cholecystectomy

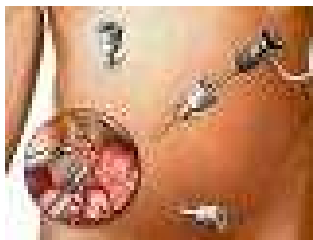

Figure 71. Trocars placed during a laparoscopic appendectomy

7. BASICS OF THE LAPAROSCOPIC SURGERY

Nowadays, the reduction of the surgical load is characteristic in the surgical interventions. The laparoscopic technique which basically changed the classic surgical mentality, was the milestone in this aspect of thinking. It was certified that the extent of the surgical incision plays an important role in the patient's recovery. The multidisciplinary approach replaced the virtuoso surgeon -who could solve everything alone- and certified that the technique is able to improve the surgeon's skill and his operative possibilities.

In 1902 Kelling called the method as laparoscopy. A word of Greek origin which means: the inspection of the soft tissue (αραπαλ: soft tissue, κσκοωεπ: inspect).

The technical developments, training operations and the patients' increased demands for the minimally invasive surgeries contributed to the wide spread of the laparoscopic surgeries

7.1. History

1901: D.O. Ott (Saint Petersburg) gynecologist – *ventroscopy*: through a colposcopic orifice:
head mirror + speculum

1901: G. Kelling (Drezda) – *coelioscopy* with a cystoscope and in an dog,
pneumoperitoneum for the first time

1910: H.C. Jacobeus (Stockholm) – *laparoscopy* for the first time in human

1929: H. Kalk -135° forward viewing optic (i.e.lens system): air between the lens

1933: C. Fervers – laparoscopic adhesiolysis

1938: János Veres (Kápuvár) – pulmonologist – treatment of the pneumothorax
special needle to create the pneumoperitoneum

1960: K. Semm (gynecologist) - automatic insufflator, appendectomy

1966: H.H. Hopkins – optical system: instead of air, glass tubes are between the lens (loss of
light ↓)

1985: E. Mühe: first cholecystectomy "keyhole surgery" – lecture without any response

1987: P. Mouret - laparoscopic cholecystectomy. Although he did not published anything
about it. However, they consider him as the person who performed the first
laparoscopic
cholecystectomy

1990: first laparoscopic cholecystectomy in Hungary – Pécs, Tibor Kiss

7.2. Comparison of the open and laparoscopic techniques

Disadvantages of open surgery

- big exposure , more operative trauma
- the postoperative pain depends mostly on the size of the surgical wound
- it is harmful to keep the body cavity open for a long time (vaporization, drying, etc.)
- danger of secondary injuries during exposure (i.e. intestine, spleen, lung)
- the increased possibility for later adhesions
- the bigger the wound is, the higher the possibility for postoperative complications (i.e. infection, hernia, etc.) is

Advantages of the laparoscopic technique

- smaller exposure, less operative trauma
- less postoperative pain
- reduced numbers of wound infection and hernia
- less postoperative adhesions
- shorter postoperative healing period and duration of the hospitalization
- cosmetic advantages

7.3. Instruments and steps of the laparoscopic surgeries

7.3.1. Creation of a pneumoperitoneum

The space needed in the abdominal cavity to perform the laparoscopic surgeries is produced by insufflating it with a gas. This is called the generation of the pneumoperitoneum. At the beginning it was done by pumping the air into the abdominal cavity. Nowadays, CO₂ due to the following characteristics is considered to be a safe gas:

-it is absorbed rapidly by the peritoneum,

- it is dissolvable in the blood,
- it is excreted rapidly from the body, and
- it can be used simultaneously with the electrocautery device with no danger of the explosion.

Disadvantage: The chance for development of cardiac arrhythmias is more in the case of application of CO₂. Due to the danger of the hypercarbia, it is very important to monitorize the patient. To create a pneumoperitoneum, we use the Veress needle (Figure 72.).




Figure 72. Veress needle

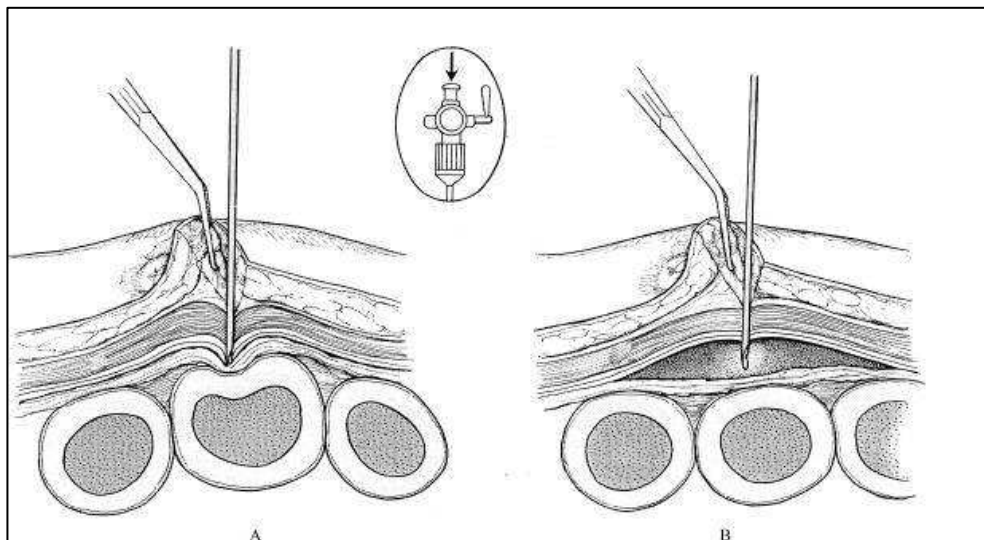


Figure 73. Insertion of the Veress needle into the abdominal cavity

The internal part of the needle, which is a blunt obturator, retracts on contact with abdominal wall to reveal a cutting tip to enter- without any difficulty -into the peritoneal cavity. Following removal of the resistance, the blunt obturator comes out again to prevent injury to the abdominal viscera (Figure 73.).

The insufflator is maintaining the pneumoperitoneum. From standpoint of the safety of the surgery, it is necessary to monitorize the intraabdominal pressure, the flow rate of the gas, and the volume of the used gas continuously. To avoid the over-insufflation, which can hinder the venous return, the intraabdominal pressure should be less than 15-20 mmHg. The safety system of the modern insufflator prevents the pressure exceeding the set limit (e.g. 15 mmHg) (Figure 74.).



Figure 74. Insufflator and its connecting gas tube

7.3.2. Entry into the abdominal cavity

Once the pneumoperitoneum is established, a “trocar-port” assembly must be inserted to allow the passage of the laparoscope and operating instruments into the peritoneal cavity. The main parts of a trocar-port assembly are: spit (or obturator, or trocar), cannula (or port), and the valve.

The length, thickness, and the shape of the tip of the trocar can be different. The automatic trocar-port is supplied with a safety shield that reduces injury to organs during insertion: it has a plastic safety shield that retract to expose the sharp tip during the insertion, and spring back upon entry into the peritoneal cavity. In the most up-to-date trocar-port the trocar itself spring back after entering into the peritoneal cavity.

The port (cannula) is furnished with a valve. It makes possible to insert the optic and different working instruments into the abdominal cavity. The tissue parts can also be removed through the port. The external diameter and the length of it can be between 5 to 25 mm and 11.5 to 17 cm respectively. The valve, which is a springy metal inset lying perpendicular to the axis of the port, prevents the gas to escape from the abdominal cavity. The automatic so-called „tilting valve” is opened by advancing the instrument in the port and is automatically closed after removal of the instrument (Figure 75.).

There are many holes at the distal part of the port. These let the gas enter into the abdominal cavity without needing to reach to the distal lens of the optic, which otherwise will lead to the disturbing condensation of the optic. These holes also prevent the intestinal injury during the removal of the port which can happen due to the appearance of the vacuum effect at the end of the port. The sideward gas tap of the port let the continuous replacing of the lost gas. The sealing cap located at the proximal end of the port is firmly surrounding the inserted optic or instrument preventing the escape of the gas.



Figure 75. Trocars

A. A disposable trocar with the safety shield, B. Trocars with reducers, C. Corkscrew trocar

The insertion of the first trocar-port is usually done in a blind manner which can lead to serious complications if the vessels, intestines, or other abdominal organs are injured. Although the possibility for such injuries are low, it is especially advisable to insert the first trocar-port under direct vision especially when you are operating on a patient who already had an abdominal operation. In such a case with making a small incision on the abdominal wall we gain access to the peritoneal cavity and when we become sure of the safety, then we insert the trocar under the direct vision. The incision is made tight around the port with

application of sutures at the edges of it. This will prevent the gas to escape (Figure 76. and 77.).

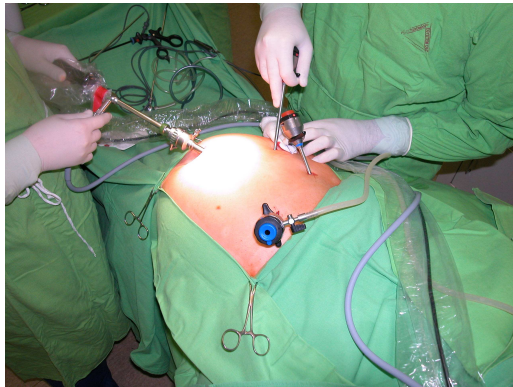


Figure 76. Insertion of the laparoscopic trocar

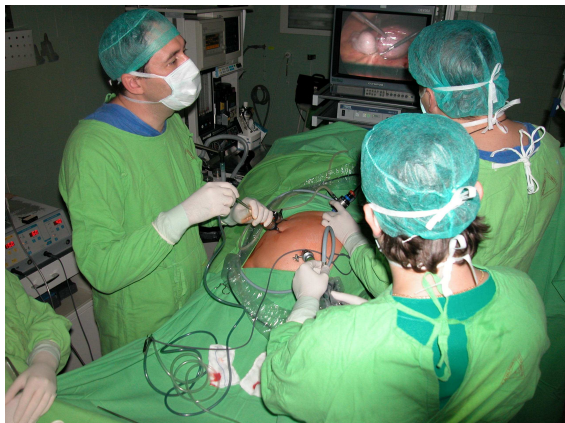

Figure 77. Clinical setup in a laparoscopic cholecystectomy

7.3.3. Conditions for inspection of the abdominal cavity, optic

The laparoscope consists of a lens system and an objective. In practice, the Hopkins' optic is used most frequently. In such an optic the spaces between the lenses-instead of air- are filled with the glasses. This increases the light transmission, decreases the light absorption (by almost 70%) and so leads to an improvement in the quality of the picture (Figure 78.).



Figure 78. Optics

The optical characteristics of the laparoscope are determined by: visual angle, visual field, focal length, and the light loss.

The bigness of the visual angle is marked by the closed angle that is made by the axes of the objective and other lenses of the laparoscope which depends on the direction of optics. The 0°

laparoscope provides a straight forward view, and the 30° laparoscope a forward oblique view. The visual field means: "how wide(or broad) the optic see".

Light source

Illumination of the abdominal cavity is of a basic importance for orientation and suitable carrying out of the surgical steps. Currently, a 150–300 W fan-cooled xenon light source is used to provide color-corrected light for extended periods of time without overheating. The illumination is transmitted to the laparoscope via a flexible fiber-optic light guide (180–250 cm long).The camera is connected to the optic.It recieves the arriving picture and transmit it to the monitor (Figure 79. and 80.).

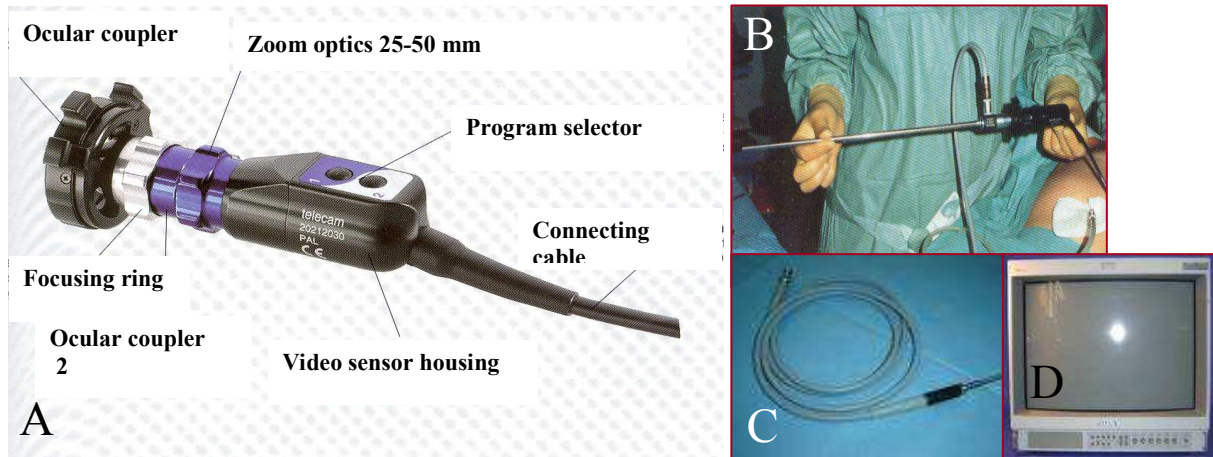


Figure 79. Laparoscopic camera (A), Optic and long connected light cable and camera (B), Light cable (C), Monitor (D)

Laparoscopic irrigation/suction device:

It is a necessary device in laparoscopic surgeries. Its central unit is continuously producing a 180 mmHg positive- and a 500 mmHg negative pressure. These effects can be applied into the abdominal cavity with the help of tubes and a valve. As an irrigating solution, we use the warm saline solution.



Figure 80. Laparoscopic tower

A. Monitor, B. Insufflator, C. Light source, D. Electrocautery device, E. Video device, F. Irrigation/suction device

Electrocautery devices

They are similar to those used in open conventional surgeries and can be either mono- or bipolar. In a monopolar system the circuit of the electric current is made by the active electrode (i.e. hand-held instrument), the patient's tissue, and the ground pad (i.e. the indifferent electrode). It can possibly cause burn injury of the distant tissues. A bipolar system, in contrast, places the tissue between two electrodes, so the current passes from one electrode to the other through the interposed tissue. In this manner, it is safer than a monopolar system.

Laparoscopic hand instruments

For videoendoscopic surgeries special instruments are needed which are different in sizes, lengths and forms from those used in the open conventional surgeries (Figure 81., 82., and 83.).

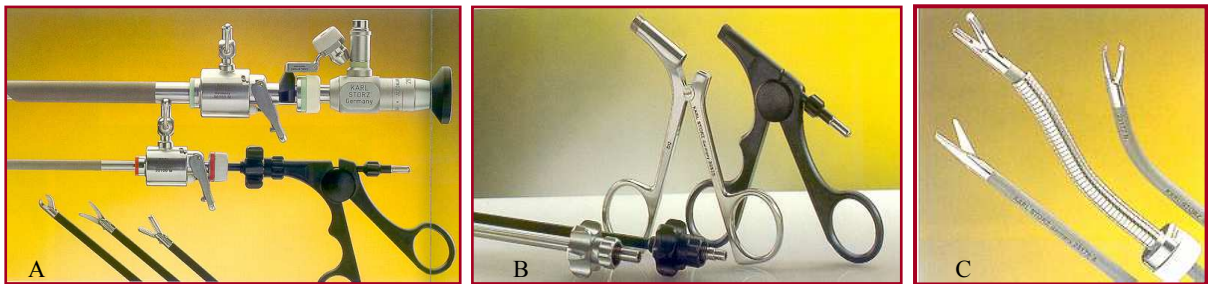


Figure 81. Laparoscopic hand instruments

A. 5-mm and 10-mm ports with instruments, B. Insulated (black one) and non-insulated graspers, C. Flexibel instruments




Figure 82. Laparoscopic dissector (A), scissors (B), grasper (B), Clip applier with titanium clips (D)

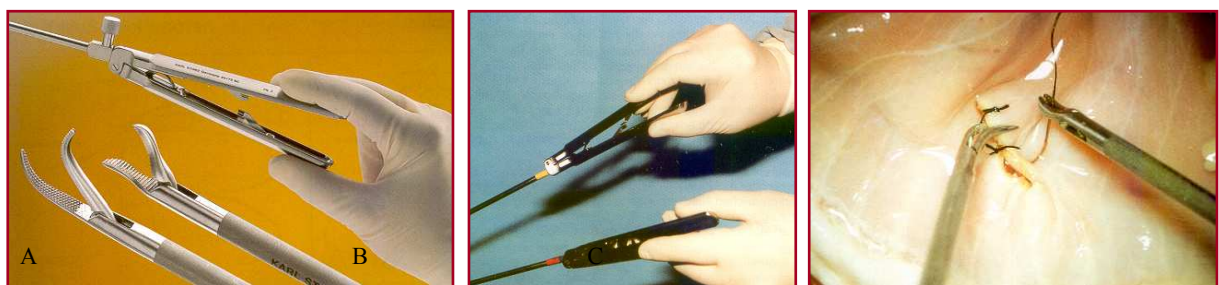


Figure 83. Laparoscopic needle holders ("parrot" and "flamingo") (A), Correct holding of the needle holders (B), Intracorporeal sutures (C)

Difficulties of the laparoscopic technique:

- Two- dimensional approach and three- dimensional activity
- Eye-hand coordination
- Feeling the depth
- Coordinated use of the dominant and non-dominant hands
- Lack of the tactile sensation
- Magnified surgical territory and finer manipulations
- Fulcrum effect
- Limited movement
- New and unusual instruments
- Continuous care of the technical equipment
- Increased physical and mental demands

The laparoscopic technique – due to its known benefits- became extraordinarily famous. In spite of this, the application of this method is not easy and needs too many practices. Immediately following entry into abdominal cavity you do feel the unusual orientation. The instruments (which are completely different from the usual and accustomed ones) with respect to the characteristic of the optics actually move in a direction opposite to the surgeon's aims. Even a very simple activity (e.g. knotting) becomes possible only after many hours practices. It is obvious that to become expert in laparoscopic surgery is not possible with performing it on patients. You can get experiences with practising it on a pelvitrainer and -after getting enough experiences - animals.

8. BASES OF THE MICROSURGERY

” None of the surgical interventions can eliminate the use of the appropriate magnification, even if their task is only to separate the tissues. ” (Bernard O'Brien – Melbourne)

8.1. Introduction

One of the most important educational activities of our department is to organize and hold the microsurgical practices. As a matter of fact, microsurgery is a shortened name referring to those surgical activities, which are performed by the help of microscopes. This surgical method (i.e. microsurgery) was accompanied by an initial enthusiasm originated from the success of microsurgical interventions performed on small vascular and neural structures in the 1960s. It was a motive for the later wide-range clinical spread of the method. It made possible the development of new techniques e.g. transplanting a free graft or replantation of an extremity in the 1970s and 1980s. As a result of these, microsurgery became an indispensable part of not only surgery but also all the other manual medical activities of nowadays. Due to these, the practical teaching of the microsurgery became correctly an integrated part of the medical educational programme.

The microsurgery is not only a technique or a combination of theoretical knowledge and practical proficiency, but it is a proper approach that is not dispensable in the extended surgical field. The shortest way to understand the essence of the atraumatic surgery is getting acquainted with the microsurgery. During the acquirement of this technique we have to look through another lens (i.e. lupe or microscope) and learn again the basic techniques of handling of various tissues, the preparation methods running with minimal injury, the ways of cutting the vessels and nerves, as well as the insertion of precise stitches. It occurs that some students do not put enough effort for it and they hurry too much in completing the microsurgical course. We do advise them to spend as much time as possible to get knowledge about and practise this technique. Considering the fact that the practices are built on each other from the simpler to more complicated ones, we advise them keeping the order of the practices.

It is not too easy to determine the place of the microsurgery as an "art" in surgery, because this method is used by many surgical professions including neurosurgery, traumatology, ophthalmology, oto-rhino-laryngology, maxillo-facial surgery, plastic surgery, urology, transplantation surgery, pediatric surgery, obstetrics and gynecology, dentistry, etc. Microsurgical procedures are defined as surgical interventions performed under optical magnification (e.g. lupe or operating microscope) with special operative devices and auxiliary materials. Microsurgery, however, does not only mean the use of special instruments, it also necessitates the possession and application of thorough topographic anatomy and own surgical strategies. It is important to note that the term "*micro*" is not completely synonymous with size, although most of the interventions are performed on structures which are at least one order of magnitude smaller than in macroscopic surgery and the proportions can be visualized only with optical magnification. The major indication of microsurgery is approximation of vessels and nerves with **1.** re-establishment of anatomical connections or **2.** construction of new connection. These techniques can be used in all such surgical interventions where the sizes of the structures are in the millimeter range or when we are working in proximity of specifically sensitive structures (i.e. brain, nerve fibre, etc.).

"*Micro*"-surgery requires a higher level of cerebro-manual activity and acquisition of special skills. These aims can be achieved by a special attitude that is quite different from that of the conventional surgery. Dynamism is inherent component of general surgery, but this should be replaced by a thoughtful and flawless trouble shooting. Accordingly, microsurgical procedures pose considerable challenge for everyone since reduction of mistakes and

improvement of surgical competence can be achieved only by a substantial amount of practical learning.

8.2. Terminology

Microsurgery is defined as a surgical technique in which incisions, dissections, and sutures are performed with optical magnification usually with the aid of an operating microscope.

Neuro-vascular microsurgery is a field of microsurgery in which the anastomosis of the peripheral nerves and vessels smaller than 2 mm in diameter is realized with the intent of reinnervation or revascularization of limbs or tissues. Such techniques are applied in replantation procedures in reconstructive microsurgery.

Reconstructive microsurgery is a surgical field that uses the transfer of revascularized tissue in order to correct congenital or acquired defects.

Experimental microsurgery is developing continuously because these techniques are initially tried and studied in a laboratory and then applied in clinical practice. It is used in three major areas: 1. research of the biological phenomena, 2. design and improvement of new operating techniques or biomaterials, 3. teaching of vascular and neural microsurgical techniques.

8.3. History of microsurgery

The microsurgery has evolved in the course of development of microvascular experiences. Among the most important achievements in vascular surgery are the triangulation method used in making anastomosis and the fact that adjustment of the intima-to-intima has an important role in reducing the thrombus formation. These were found by Charles Claude Guthrie and Alexis Carrel.

Of course, for a wide-range utilization of these results in the clinics it was indispensable to develop the instruments used for interventions suitably. The first clinicians who were dealing with microscopic surgery after a short time recognized that the finesse of hand movement is actually limited by eyesight. As a result, Nylén began the use of the operative microscope. Thus, in the history of medicine the microscope appeared in the surgical theatre. Actually, this can be considered as the time when the clinical microsurgery was born. Parallel with this, the refinement and specialization of hand instruments and devices took place. These were completed by the appearance of the atraumatic suture materials. The eye of the surgical needle and the presence of the double string at this part of the needle can notably damage the tissue when they pass through it. This is not allowed in joining of the tissues in microsurgery. Therefore, the development of the atraumatic suture materials (i.e. appearance of the needle-string unit) was an important innovation. It eliminated the possibility for creating a big dead space around the string, as well as the damaging of the tissue. Doing so, it reduced the chance of the bleeding and infectious complications. The microsurgical knowledge, techniques and instruments developed in the following orders:

Creation of the microscope

The history starts from the ancient times. Lucius Annaeus Seneca (4 BC-65 AC) wrote that we could see the letters bigger and more clearly using a glass globe filled with water. His student and follower Nero (Lucius Domitius Ahenobarbus, AC 37 -68) used a lense made of grind emerald. In 1280s Roger Bacon (1214-1294,) a Franciscan monk, used a

magnifying glass for reading. With the use of magnifying lenses the history of the microscope started.

1590: Hans and Zacharias Janssen (1580-1638), father and son - Dutch spectacle makers - produced the first compound microscope, which was made of double convex and double concave lenses. The magnification ranged from 3 to 9 x.

1612: Antonio Neri (1576-1614) developed the lead crystal glass. It also contributed the work of George Ravenscroft (1632-1683) in developing clear lead crystal glass (also known as flint glass) in England in 1674.

1625: Giovanni (Johannes) Faber (1574-1629) coined the term “microscope” (from the Greek: *mikron* = “small” and *skopein* = “to look at” or “see”).

1665: Robert Hooke (1635-1703), an English scientist published *Micrographia*. Upon examination of the cork pores with his microscope, he decided to call them "cells".

1670: Antonie van Leeuwenhoek (1632-1723) from the Netherlands, was a lense grinder and a scientist. He was the inventor of the modern microscope (he was also the doorkeeper of town hall). His lenses had magnifications of up to 270 x.

1685: Cherubin d’Orleans (1613-1697) invented the binocular telescope.

1744: John Cuff (1708-1792) built the first metal microscope.

1872: Ernst Abbe (1840-1905) invented the apochromatic lense system for microscopes. It was an important breakthrough, which could eliminate the primary and secondary distortion of microscopes.

1888: Carl Zeiss (1816-1888) marketed the apochromatic microscope objective. The director of his factory was Abbe. This objective was the first one with a magnification of 108 x and an aperture of 1.6.

1921: Carl Olof Nylén (1892-1978) used the microscope to do a microsurgical operation (i.e. treatment and drainage of a chronic otitis) for the first time. Following this, Holmgren used the operative microscope for treatment of numerous oto-rhino-laryngologic diseases.

1953: The Carl Zeiss Company marketed the first modern operative microscope, with which it was possible to perform different microsurgical interventions.

A brief history of microvascular surgery

1552: Ambroise Paré (1510-1590) was the first who applied ligature to manage bleeding. He ligated the vessel together with the surrounding tissues, which differed from the nowadays practice. Till the 18th century the hemostasis was performed by means of ligatures, burning, and compression. Thereafter, the ligature was considered as the best method for hemostasis.

1877: Nikolai Eck (1847-1908), a Russian surgeon, created a porto-caval shunt with running silk sutures in 8 dogs, from which one stayed alive for 2.5 months after operation.

1891: Alexander Jassinowsky of Odessa performed the first successful experimental arterial anastomosis on living animals. He performed interrupted carotid arterial sutures in dogs, horses and calves.

1897: The first arterial anastomosis in a human by John B. Murphy (1857-1916) in Chicago. He investigated the proximal end of the femoral artery into its distal end, and then fixed it with stitches.

1912: Alexis Carrel (1873-1944), a French surgeon, developed the triangulation method for suturing blood vessels, thus he established the bases of the modern vascular surgery. In 1912, he was awarded the Nobel Prize in medicine and physiology due to his work related to the vascular anastomosis. He worked together with Charles Claude Guthrie.

1935: Gordon Murray (1894-1976) introduced the anticoagulant "heparin" to the world clinical practice in Toronto. He used cleaned heparin intravenously to treat and prevent thromboembolism.

1945: In the World War II, working on vessels with a diameter of 2-3 mm became a routine intervention in vascular surgery.

1958: Sun Lee ("the father of experimental microsurgery") described the bases of side-to-side porto-caval shunt on rats in the Pittsburgh University. Several microsurgical instruments were developed by him.

1960: Julius H. Jacobson and Ernesto L. Suarez of the University of Vermont described microvascular surgery using a microscope to aid in the repair of blood vessels with 1.4 mm in diameter. They applied the hand instruments which were used by jewellers and transformed them for to be used in plastic surgery. The majority of interventions were performed on the nose, ear and the maxillo-facial region.

1962: On May 23, Ronald A. Malt and Charles F. McKhann at the Massachusetts General Hospital performed the first replantation on a 12-year-old boy who had his right arm amputated in a train accident.

1964: Harry Buncke (considered to be the "father of reconstructive microsurgery") reported the first successful rabbit ear replantation.

1968: Raymond Madiford Peardon Donaghy and Mahmut Gazi Yasargil founded the micro-neurosurgery. They worked out the method of intra- and extracranial arterial bypass at the Vermont University, which could significantly improve the perfusion of the areas supplied by middle cerebral artery.

Hungarian replantation events

1979: József Nyárády performed the first finger replantation in Pécs.

1980: Gusztáv Gulyás carried out the first successful thumb replantation in Budapest.

1982: János Aurél Simonka performed the replantation of the toe to the hand in his clinic at the University of Szeged.

1982: The first limb replantation in Hungarian was also done by József Nyárádi in Pécs.

8.4. Microsurgical instrumentation

It is essential to introduce the handling of the operative microscope and the microsurgical instrumentation before demonstration of practices, as well as to give informations about e.g. selection of an appropriate suture material or prevention of typical mistakes.

Microsurgical hand instruments

Before we start to introduce the microsurgical instruments, there is a need to mention that these are very expensive and delicate instruments, which can only be used for microsurgical interventions. Great patience is required in using them, because the inappropriate application causes them to lose their sharpness or become distorted and broken. In the case of any doubt connecting to the use of a particular microinstrument (e.g. unsuitable size) in performing a specific intervention, the surgeon should immediately stop his activity and ask for an advice.

It is also important to mention that before the operation it is advisable to control the instruments, because the unrecognized errors of the devices can considerably influence the success of the microsurgical intervention. That is why it is suggested to have your own instrumentation if you want to deal with the microsurgery in a professional way. Doing so, you will have individual responsibility for them.

Forceps

The iris forceps is primarily used to grab soft tissues. The internal surface of its tip is serrated similar to the anatomical forceps. The straight, fine-tipped jeweller forceps (i.e. Adson forceps) is used to grab or lift the tissue and tie the thread. In closed position, the grab-surface should be at least 3 mm, this makes the grip secure. The curved jeweller forceps is properly suitable to prepare the vessels. It can easily be inserted under the vessel to prepare it. The vessel dilator is virtually a modified jeweller forceps, the grab-surface is smooth and the tip is rounded. By inserting it into the lumen of the vessel it can easily be opened up. Beside this, it is suitable for the counter-holding during the suturing.

Needle holders

The needle holders are used to grab the needle and have various size and shape (supplied with flat or cylindrical handle and with or without a locking mechanism). Needle holders without a locking mechanism are preferably used in microsurgery.

Scissors

The dissecting scissors are characterized by a springy handle, a slightly curved blade and a rounded tip. This latter characteristic is necessary to avoid damaging the vessel wall during preparation. Adventitia scissors are used for removing the adventitia layer from the ending of the vessels; it is characterized by a straight blade and a fine, spiked tip. It is also suitable for cutting the thread, as it does not fracture it.

Approximator, microvascular clip, clip applicator

Approximator is such a haemostat with two tips, which can be slipped along a single axis toward each other and can be fixed in these positions. It makes possible to put the ends of the joining vessels in a right position, to keep them close to each other, as well as to turn the anastomosis around the longitudinal axis of the vessel. In this manner we are able to suture the posterior wall of the anastomosis. The tips of this device grasp the vessel but do not damage it.

The clips are very fine devices for temporary coagulation and exclusion of the circulation. The same as the approximator, they can grasp the vessel but do not damage the adventitia.

The clip applicator is similar to an anatomical forceps, but it is a little bit thicker than it. Its end is shaped according to the type of the approximator or clip which is applied with it. The approximator and the clip can be applied ONLY by this device. It is strictly forbidden to apply them with any other forceps or Péan.

Protection and maintenance of the devices

If we want to use our instruments for a longer period of time, we have to handle them carefully. The followings should be taken into consideration:

1. Their tip should not come in contact with hard surfaces, otherwise they can become distorted.
2. You must not put the instruments down with their tips facing downwards.
3. Always put them at a safe place, from where they can not fall down.
4. It is important to keep only one instrument in your hand at a time.

It is advisable to soak the instruments in a bath containing hemolytic enzymes for 30 minutes, after which even the most persistent blood contamination can be easily washed off and cleaned by toothbrush. The most suitable cleaning is the treatment in a heated ultrasound bath. The careful drying is important after washing. Even minor maintenance works (e.g. sharpening, oiling, grinding, etc.) should be done by a specialist. The microsurgical instruments can be securely stored and transported in metal sterilization containers. Besides the cold sterilization, the devices can also be sterilized in autoclave. First, we put a textile cloth and a silicone sheet inside the container, and then the instruments are laid down on these. The projecting teeth of the silicone sheet prevent the instruments to move and knock against each other inside the container during transportation. To further eliminate the moving of the instruments, a small textile cloth is placed inside the container to tightly fill up its inner part. The utilization aims of the instruments (e.g. name of the operation, or “basis set”, etc.) can be stated on the external surface of the container.

Coagulation, bipolar coagulator

In microsurgery to manage a bleeding, a special, modified type of the bipolar coagulator is used. In monopolar coagulation, the electricity passes through the tissues from the active electrode to the neutral one. While in bipolar coagulation, the electricity passes only through the tissue which is located between the tips of the forceps. Since in bipolar coagulation the electric current is passing from one tip of the forceps to the other one the thermal effect that produces the coagulation can be controlled well. As a result of this, the damage to the surrounding tissues can be avoided. A common problem is the sticking of the forceps to the tissues. This can be prevented by the following means:

- Use the coagulator at the lowest degree:
- Keep the tips of the bipolar forceps and the tissues always moistened.
- Do not squeeze the vessel walls between the tips of the forceps. Instead, gently touch and slide the tip of the forceps back and forth obtaining a considerable coagulated surface.
- During operation clean the tips of the forceps frequently and moisten them with gauze swabs.
- During coagulating a big vessel, in order to protect the proximal part from the emitted heat pull it apart with another forceps.

Microsurgical threads

We use cylindrical microsurgical needles with 8/0, 9/0, 10/0, and 11/0 monofilament threads in practices. The needle can be 200, 140, 100 and 50-75 μm in diameter. The former needles are used in basic practices, while the latter ones are used in more complicated operations.

Magnetization

In introducing the instrumentation we have to mention the problem of their magnetization. Sometimes, it may happen that the instruments become magnetized, if they come in contact with a device that has some magnetic or electromagnetic parts. Similar thing is experienced during training practices, when we insert the sutures into a latex sheet. In this case the synthetic thread can become electrostatically charged while it passes through the latex. Under such circumstances it is advisable to purchase special equipment that is able to eliminate the magnetization. Without doing so, grabbing of the metal needles or even the synthetic threads will become difficult.

1. Practice

The basic rules of the behavior in the operating room, scrubbing-gowning-gloving, preparation of the operation area

Entering the operating room the following machines and devices can be seen: anesthetic machine, laryngoscope, cannulas, endotracheal tubes, anesthetic drugs, gauzes, infusion stand, infusion set, ECG monitor, pulzoxymeter, defibrillator etc. At the headboard of the operating table there is a guard, which shields the non-sterile area of the anesthesiologist from the sterile operative field. The guard is for the fixation of the isolation sheet, and must not lean on it, or cross it over from any direction threatening the asepsis.

The small instrument stand (Sonnenburg stand) can be found at the leg side of operating table. The most frequently used instruments, threads, and sponges are situated on it. Kick bucket for soiled sponges and instruments stands at the side of operating table. The electrocauter is also placed at either side of operating table. The operating lamp can be positioned to any directions, and gives cold, and convergent light. Autoclaves or other devices for sterilization may also be found in some operating rooms. Microwave oven is for the heating of the infusion solutions, which is important for the rinse of the operating field. Central or portable vacuum devices can also be found in the operating room. Sterile boxes (Schimmelbush container) containing sterile gowns, drapes, sponges are placed on a stand at the side of the operating room, and can be opened by a foot pedal.

Persons entering the operating room should wear face mask and surgical cap. There are different kinds of caps for persons with short and long hair. The cap should cover the hair completely. The loose cap threatens the asepsis, the too tight is uncomfortable to wear for a long period of time. Taking on the cap is followed by the single use mask, which should cover the nose and mouth too. Those parts containing a wire should gently push to the nose, which provides the stability of the mask during talk and movement of the cheeks. Facemask prevents contamination from saliva during talking and coughing. The efficacy of filtration depends on the number of layers. The mask on the film has three layers with good filtration efficacy. The white side is the face side, the green is the outside. The upper knitters recommended to tie at the crown, while the lovers at the nape. It is important to emphasize the concordance of asepsis and comfort. Masks should be changed between operations or immediately when they become wet. In certain cases (e.g. cardiac surgery) wearing of two masks can even be advisable. Spectacles might stem up because of the exhaled warm air. Special masks can be purchased for spectacled persons.

Entry into the operating room is allowed only in operating room attire and shoes worn exclusively in the operating room. All clothing except underwear must be changed to scrub clothes. If the arms of the scrub clothes covers the elbows they have to fold it up. It is advisable to fix long hairs with rubber ring or hair grip, and cover by surgical cap thereafter. Nails should cut short at home the day before the scrubbing procedure because of the possible micro injuries. Because of similar reasons brushes are not used in scrubbing nowadays. Watch, rings, bracelets, nail polish should remove from the hands and arms before scrubbing. Hands and arms up to the elbow should be clear and free from any strange or artificial matter.

Scrubbing is a two phase procedure. The first phase is the mechanical cleaning, the second one is the disinfection. For the mechanical cleaning one have to push 2-3 dose of liquid soap to the hand, and opening the tap with the elbow a rich foam have to make up. Rub each side

of each finger, between the fingers, the back and palm of the hands, and the forearms from the wrist to the elbow. There is no time limit of this procedure, it depends on the impurities of the hands, but it must be thorough. Rinse the foam from the hands and arms with water, always keeping the hands above the level of elbows, and allow the water to drain off the elbows. So you can prevent contamination of the hands with dirty foam. Do not remove the water from your hands by shaking it off. Water tap have to close by the elbow. Wipe your hands and forearms by a single use paper towel, and the disinfection phase starts. The exact duration of disinfection is given by the manufacturers, you should insist on it to assure the efficacy of disinfection. Sterillium[®], Desmanol[®], Skinman soft[®], Descoderm[®] are the most widely used disinfectants with the following obligatory protocol. Hold your palm below the dosing apparatus and push 2-3 times the feeder with your other elbow to take a proper dose of disinfectant. Rub the hands and arms thoroughly from the tip of the fingers to the elbow with the antiseptic exactly for 1 minute. Repeat the process 4 times, but the disinfected area on the forearms will be smaller and smaller. The second time it extends to 1/3 under the elbow, the third time it extends to the middle of the forearm, in the fourth minute it extends 1/3 above the wrist, and finally the fifth dose is rubbed only the hands. So the disinfectant exerts its effect on the hands for 5 minutes. You should rub your skin only if it wet, rubbing the dry skin is ineffective. In this case you should take disinfectant again and continue the process. Rubbing must be thorough, do not fondle the skin, but rub it extensively not only to the palm and back of the hands, but also to amongst the fingers, curves of hands, around the nails, and the forearms. Keep always the hands above the level of elbows during the whole scrubbing process, and allow the disinfectant to drain off the elbows. Do not touch any non-sterile object during scrubbing. If it occurs, you should start the disinfection phase from the beginning. Avoid your eye from the splash of disinfectant, because it may irritate it.

Scrubbing is followed by the gowning procedure. Sterile gowns are specially folded. Hold the gown at the edge of the neck piece away from your body and allow it unfold gently while holding it sufficiently high that it will not touch the floor. Gently shaking the gown insert both arms into the armholes, keeping your arms extended. The cuffs of the gown can pull over the wrist. Wait for the scrub nurse to assist you by pulling the gown up over the shoulders and tying it at the back. So the back side of the gown will be non-sterile. Do not touch the assistant or any non-sterile surfaces. If it happens to do, then you should start the disinfection and gowning procedure again. General rules of asepsis are very important during scrubbing and gowning too. Do not touch anything non-sterile, do not flounce endangering the sterility. Do not dangle your hands, hold it always above the level of the elbows. Do not touch your cap or masks even if it is uncomfortable or slipped. Ask a non-scrubbed person to adjust it.

Rules of gloving. The scrub nurse holds one of the gloves so that the palm of the glove faces you. From the position of the thumb you can find out which hand to fit. The scrub nurse holds the left hand glove on the video. Put two fingers of your right hand into the opening; pull the inner side of the glove toward you so that a wide opening is created. Slip your left hand into the glove. When you put on the right hand glove, place the fingers of your gloved left hand under the right glove cuff to widen the opening and slip your right hand into the glove. If your fingers failed their right position in the glove you may adjust your gloves when the gloves are on your both hands.

Disinfection of the patient's skin is performed after the surgical hand scrub and before gowning. Shaving must be done immediately prior to the operation. The scrub nurse gives a sterile container with three gauze sponges, and sponge forceps. An assistant pours

disinfectant into the container. Grasp a gauze ball with the forceps and sponge it with disinfectant. Washing with antiseptics is begun at the exact location where the incision will be made, moving outward in a circular motion. Do not return to the centre with the same sponge. Throw down the sponge to the kicking bucket thereafter, avoiding touching any non-sterile surfaces. Take a new gauze ball and continue the disinfection of the skin in the same way, but affecting only a smaller area preventing the contamination from non-washed surface. Throw down the sponge again, and use the third sponge on a smaller surface. The direction of disinfection is from the clean to the contaminated surface if there is a source of infection on the skin (e.g. fistula, anus praeternaturalis). In opposite way we may disperse the bacteria on the skin. The disinfected area must be large enough for the lengthening of the incision during surgery. Disinfection of the skin is followed by gowning and gloving.

After the skin disinfection the operating area must be isolated from the non-disinfected skin surfaces and body areas by the application of sterile drapes and other sterile accessories. The first sheet (200x140 cm) isolates the patient's leg. Two scrubbed person standing on the each side of the operating table holds the sheet, and pulling out the inner fold unfold it, and covering the lower side of the operating area with the folded side, and operating table with the single side. The second sheet (140x100 cm) is used to isolate the patient's head, covering the upper side of the operating area with the folded side, and the guard with the single side. Placement of the two side-sheets (80x80 cm) then follows. Unfold them completely, then fold 1/3 of them back to the table and isolate both sides of the operating area. The isolation should cover the patient and the operating table completely. It is forbidden to let your hands beneath the level of the operating table throughout the isolation and the operation. Backhaus towel clips are usually used to fix the isolation sheets to the skin. The clips have to position from the centre to the periphery, not to hamper the operation procedure. The sheets are also fixed to each other and to the guard by Schaedel towel-clips. If the isolation becomes wet during operation, it must be covered by a new layer without removing the original one.

2. Practice

Introduction of basic surgical instrument and practicing their use

Tissue dissection:

1. Conventional scalpel: handle and blade is together, blade cannot be changed. Handling of scalpel can be performed in two ways. One is the fiddlestick handling used by long straight cuts. Handle is positioned horizontally holding between first and third finger, held from upside by the second finger, fourth and fifth finger are encompassing the remnant part of the handle. (The other type of handling is the pencil handling used by short cutting, it will be showed during 9th practice.)

2. Scalpel's handle: it can be re-sterilized; on one end single used scalpel blades can be taken.

3. Scalpel blades: for single use only, blades are sterile packed singly. Blades are numbered 10-24 based on size and shape. On figure sterile opening of package and giving to scrub nurse can be seen.

4. Handle and single use scalpel blade: the blade is put on handle immediately before operation. High attendance must be taken because of danger of injury. Correct way is shown by a raffle. On figure correct handling of scalpel can be seen.

5. Cutting of the skin: after planning of cutting's length skin must be tensed by left hand (in case of left handed person it is made by right hand), and pressing slightly the scalpel whole depth of skin must be cut through. By this way formation of irregular margins can be avoided (which can cause higher scar formation). It can be seen that cutting with scalpel performs in every case sharp margins. The affected and bleeding vessels must be salved.

6. Apart from scalpel scissors are used most frequently for tissue dissection, preparation and cutting. Threads and bandages are also cut by scissors. There are scissor varying in size, shape can be straight or curved, end can be sharp-sharp, sharp-dull, or dull-dull. First introduced is used by scrub nurse, shape is straight, with dull-dull end, and it is used for cutting thread. Proper handling of scissor: first and fourth finger are introduced in the rings of the scissor, second finger is laid distally on body of the instrument fixing it. This type of holding is used in every instruments ring at the end!

7. Curved sharp-sharp scissor: can be used for cutting and dissecting tissues. Scissor must be put in the tissue with closed end, and after this scissor must be opened dissecting tissues dull. Assistant is elevating the skin using wound retractor, until operator is dissecting dull on tissue borders or cutting sharp through scared tissues. Bleeding must be salved posterior.

8. Fine, straight, sharp-sharp scissor: can be used for cutting and dissecting.

9. Fine, curved, sharp-sharp scissor: can be used for cutting and dissecting.

10. Fine, angular curved straight, sharp-sharp scissor: can be used for cutting and dissecting.

11. Lister's bandage scissor: it is angular curved; one of the blades is longer than other, there is no cutting edge on dull end. This is for avoiding damage of patient's skin during removal of bandage.

12. These instruments (Kocher, Péan, Mosquito, and Lumnitzer) are suitable for tissue dissection, grabbing, and haemostasis also. All they have got variant of straight and curved. At first Kocher can be seen, teeth at the end. This is suitable for grabbing strong tissues. It is not good for dissection because the teeth at the end can cause damage. Proper handling: first and fourth finger are introduced in the rings of the scissor, second finger is laid distally on body of the instrument fixing it. For fixation of grabbing it contains a lock system. Opening: one ring must be pressed down by first finger, while the other ring must be elevated by fourth finger. This opening technique must be performed by both hands.

13. Péan hasn't got any teeth at the end, that's why it is suitable for dull dissection, atraumatic grabbing of tissues, and haemostasis. For example on the avascular side of mesentery Péan can penetrate through without bleeding. Closing the vessel with two Péans, it can be cut through and the vessels end can be ligated by threads. In order to minimize the amount of left thread, thread must be cut 2-3 mm. distal from the knot. Scissor must be slid by assistant towards the knot, it must turned a bit (leaving back short end), and without endangering knot safety both ends of the thread must be cut.

14. Curved Mosquito: it is smaller and finer instrument as Péan. It can be used for fine preparation, for grabbing smaller particles, and stopping smaller bleeding.

15. Curved abdominal Péan: suitable for grabbing and preparation of thicker parts of tissues.

16. Lumnitzer vary form Kocher in size (it is longer and bigger). Suitable for grabbing big tissues or sponges, and because of the teeth elevation of tissues can be performed using this instrument.

17. Dissector: stick is long; end is curved in 90°, with rings at the end without lock system. It is suitable for atraumatic dissection.

18. Electrocautery can be monopolar or bipolar. At first monopolar diathermy is introduced which can be used both for cutting tissues and coagulation. Sterile cable's end must be connected to the central unit. The other sterile part must be clamped to the isolation. Negative pole is directly in connection with patient's skin, the hand port of the device must be grazed to the tissues or holding instrument. Pressing blue button on hand port coagulation, pressing yellow button cutting can be performed. There are also instruments working with foot pedal.

19. Bipolar diathermy can be used for finer and precise coagulation. There is no need for negative electrode, because circuit is circulating between the two parts of forceps.

20. Amputation knife: this type is sharp on both sides of blade. It is suitable for quick cutting of soft tissues (muscles, fascia, and vessels) during amputation.

21. Bone gauges.

22. Straight surgical raspator: on side is flat, other side is rounded, half circular end is slightly sharp. It is used for dull removal of tissues from the bone.

23. Hammer.

24. Charrière's amputation saw.

25. Straight saw.

Grabbing instruments:

26. For grabbing something the easiest way is to use a forceps. Forceps are varying in size; there are straight, curved and angular curved (dental forceps) types. End can be dull (anatomical forceps), hooked (surgical forceps), sharp (splint forceps, ophthalmologic forceps), or ring shaped (tumour forceps). Forceps is used to hold tissues while cutting, suturing, or during exploration, also used to grab vessels while coagulation, or to take into sponges, gauze when bleeding appears, even to evacuate blood, or to remove foreign bodies. At first a hooked forceps is introduced. Forceps has to be held as a pencil, while grabbing the shafts must be pressed by first and second finger (to ensure comfortable holding, finest movements, and widest size of movements). Forceps is like to the lengthening of the fingers. No way is to hold forceps in palm! The teeth of the hooked forceps avoid loosening of tissues, that's why there is no need to expand big pressure for safe tissue holding. For that reason for holding skin and subcutaneous tissues surgical forceps is mostly used, but vessels, parenchymal and luminal organs (e.g. bowels) mustn't be grabbed because of the danger of bleeding and perforation.

27. Anatomical forceps: end is fluted; ensuring atraumatic grabbing for vessels, luminal organs can be grabbed. On this picture a small sponge (10×15 cm.) can be also seen, suitable for evacuation of fluids (blood, tissue fluid, pus); it is multiple sheet gauze. Big abdominal sponge is also multiple sheet gauze, 30×40 cm. in size. Both sponges' margins are seamed.

28. Dressing forceps: Long instrument with ring at the end, with or without locking system. Most frequently used during washing of operation area, including a tupper. Hospital orderly is taking disinfective agent into a sterile container (mug), which contains also tupper. Using these tupper washing can be performed. Dressing forceps and tupper are used during operation for removal of bleeding, only pressing tupper on bleeding area a slice, not scrubbing it. Dressing forceps is also suitable for making tunnels in the tissues.

29. First introduced organ holder is the bowel clamp. It can be straight or curved. The inner side of the shaft is fine, contains corrugations lengthways (it doesn't damage bowel wall while grabbing it). It is a ringed instrument with lock system.

30. Gallbladder holder: mostly used during open cholecystectomy for grabbing and elevating the fundus of the gallbladder. It is a ringed instrument with lock system.

31. Duval's organ holder: end is slightly toothed. Triangular shaped, used as vascular clamp in the past. Nowadays it is used to grab skin or tongue while inserting piercing.

32. Allis' organ holder: end is slightly toothed. Used for grabbing organs (e.g. lung).

33. Lung holder: use is nowadays decreased.

34. Backhaus towel clamp: used for fixing isolation to the skin.

35. Schaedel's towel clamp: used for fixing isolation to each other.

Haemostasis:

Kocher, Péan, Mosquito and Lumnitzer belong also to this group.

36. Guiding probe (Payr): end is narrowing, slightly curved, including a ruffle.
37. Deschamp's ligation needle: 90° curved, dull ended needle.
38. Deschamp's ligation needle must be guided into the ruffle of the Payr probe.
39. Under the vessel of the mesentery Payr's probe must be led. Deschamp's ligation needle (containing thread in its hole) must be guided into the ruffle of the Payr probe. Thread must be grabbed by forceps on the other side, Deschamp's needle drawn back. Threads should be knotted and cut. Finally between two ligations vessel can be cut through.
40. Vascular clamps make reversible closing of vessels possible. One of them is Satinsky's vascular clamp, its end is curved. Particular closing of big vessels make possible, under the closing the circulation is continuous.
41. Blalock's tourniquet: it can be closed using a twist; two ends are mostly covered with rubber (atraumatic closing).
42. Bulldog: small, short atraumatic tourniquet, spring at the end.

Tissue retraction:

43. Wound hook: hanging into the wound corners and drawing the edges suturing can be performed easier.
44. Wound retractor: it is varying in size very much. It is used to elevate wound edges, establishing better visibility for operator.
45. French retractor: end is dull. Advantage is the less tissue damage; disadvantage is the easy slide out from the operating area when it is not held correctly.
46. Abdominal retractor for elevation of parts of the abdominal wall.
47. Organ retractor.
48. Self retractor (Weitlander): end is similar to wound retractor. Opening lock system ends are diverging making retraction without manual holding.
49. Self retractor (Balfour): two dull ends are inserted under abdominal wall. After making sure there is no bowel or other organ between abdominal wall and self retractor, it can be opened. Tension is ensuring retraction.

Tissue rejoining:

50. Mathieu's needle holder: it is held in palm. It has got 3 teeth. At first pressing needle is closed into the instrument, at second needle is held tight; at third pressing needle holder is opened.

51. Inserting needle into needle holder: needle should held in left hand, needle holder in right hand. Needle have to be kept in needle holder in $\frac{1}{3}$ - $\frac{2}{3}$ ratio, needle have to be positioned perpendicular to needle holder.

52. Inserting thread into French needle: 1. taking thread into the complete hole, after it drawing it into the half hole at the end of the needle; 2. holding needle holder (containing needle) in right hand also holding one end of the thread together with it; other end of the thread should be guided at the back of the needle; thread must be positioned at the end of the needle and drawn into the hole.

53. Sterile opening and taking of the atraumatic needle-thread combination: the outer bandage must be opened without touching inner bandage. Scrub nurse takes the inner bandage. Opening the inner bandage needle can be caught by needle holder, and needle-thread combination can be pulled out.

54. Hegar's needle holder: ringed end, it must be held using first and fourth finger. At first pressing needle is closed into the instrument, at second needle is held tight; at third pressing needle holder is opened. It is suitable for fine suturing (vascular, bowel, lung suture).

55. Michel's clip applier/clip remover, and skin clips are strung on a U-shaped wire.

56. Skin clip must be grabbed by clip applier and drawn away from the wire. Assistant is grabbing and elevating both wound edges using surgical forcipis (proper adaptation is very important to avoid irregular margins). Clip must be positioned between the forcipis. Clips must be taken 1 cm. distal from each other.

57. Clip removal: clip remover must be positioned under the clip in the midline, than pressed. By this way the U-shaped clip becomes straight, releasing the skin.

58. Skin can be closed also using automatic clip applier machine.

59. Skin can be closed also using adhesive sticks. These sticks (Steri-Strip[®], Proxi-Strip[®]) are suitable for closing short superficial wound without need for suturing, and for securing intracutaneous suture.

60. Tissue glues are mostly made from fibrin bases, causing consistent fibrin mesh (using last steps of the haemostatic cascade) (Berioplast[®] P Combi-Set).

Special devices:

61. Volkman's bone curette: this spoon-shaped instrument is sharp, it is used for removing tissue particles, and to refresh infected wounds base.

62. Probe: end is dull, that's why extent of fistulas can be revealed without making tissue damage.

63. Payr's stomach and bowel crushing forceps: inner side is finely fluted, atraumatic. It is suitable for crushing wall of the bowel, avoiding rupturing the serosa during ligation of the bowel. Bowel must be laid on the instrument, than closed and open. After opening the layer of the crushing can be seen, in this line the ligation must be performed.

64. Sewing machines rejoin tissues by one or two layers of clips. Clips are pressed into an anvil on opposite side, clips become hooked. There are linear (some of them include also cutting edge) and circular sewing machines.
65. Suction system, hand part is going on towards a plastic tube, which is connected through a reservoir towards the central suction system.
66. For the drainage of the operating area using a scalpel a puncture must be performed. Abdominal Péan must be drawn through the abdominal wall, and plastic tube should be drawn from inside out. After positioning in the operating area drain must be sutured to the skin.
67. Lamp set: because it is sterile, operator can set the position of the operating lamp during operation.
68. Vascular prosthesis.
69. Hernia mesh.
70. Correct opening of sterile glove's bandage. The outer bandage must be opened without touching inner bandage. Scrub nurse takes the inner bandage. Opening the inner bandage the two gloves can be seen.

3. Practice

Knotting technique and type of knots

During practice two types of knots will be introduced: Wiener knot and surgical knot must be learnt using both hands. For better visibility on “knotting table” thick threads in various colours will be used.

Wiener knot is fast to make and is suitable in case of less tension. Other hand surgical knot is strong and safe, that’s why it is appropriate in case of tension.

1. At first Wiener knot made by right and left hand will be demonstrated, after this surgical knot will be shown performed by right and left hand.

2. Wiener knot made by right hand: threads end is positioned in right hand between first and second finger ~ palm side is facing upwards ~ third, fourth and fifth fingers are lying side by side stretched ~ second finger is flexed maximally ~ the other end of the thread (held in left hand) must be laid on third finger ~ right third finger must be flexed and must reach the thread held by right first and second finger ~ this end must be grabbed by right hand third and fourth finger, while releasing it with first and second finger ~ thread must be drawn through the loop ~ knot must be pushed down by right hand second finger. At first 3 slow, than 5 quick made knots will be shown.

3. Wiener knot made by left hand: threads end is positioned in left hand between first and second finger ~ palm side is facing upwards ~ third, fourth and fifth fingers are lying side by side stretched ~ second finger is flexed maximally ~ the other end of the thread (held in right hand) must be laid on third finger ~ left third finger must be flexed and must reach the thread held by left first and second finger ~ this end must be grabbed by left hand third and fourth finger, while releasing it with first and second finger ~ thread must be drawn through the loop ~ knot must be pushed down by left hand second finger. 5 knots will be shown.

4. Knots will be shown made by right and left hand by turns.

5. Surgical knot made by right hand: threads end must be grabbed in right hand by the way that end is pointing towards fifth finger, while thread is held by flexed third, fourth and fifth fingers ~ right hand first and second finger are positioned to make “C – shape” ~ the other end of the thread held by left hand must be taken before right hand first finger ~ right hand second finger must take thread on first finger (both threads are surrounding right hand first finger, crossing each other) ~ thread must be laid by left hand on right hand first finger’s pad, while affixing it with second finger ~ it must be rolled in the appearing loop ~ knot must be pulled down by right hand second finger. 5 knots will be shown.

6. Surgical knot made by left hand: threads end must be grabbed in left hand by the way that end is pointing towards fifth finger, while thread is held by flexed third, fourth and fifth fingers ~ left hand first and second finger are positioned to make “C – shape” ~ the other end of the thread held by right hand must be taken before left hand first finger ~ left hand second finger must take thread on first finger (both threads are surrounding left hand first finger, crossing each other) ~ thread must be laid by right hand on left hand first finger’s pad, while affixing it with second finger ~ it must be rolled in the appearing loop ~ knot must be pulled down by left hand second finger. 5 knots will be shown.

7. Knots will be shown made by right and left hand by turns.

8. As repeating Wiener knot made by right and left hand, after it surgical knot made by right and left hand will be shown.

9. During the positioning of the knot it is necessary to guide the knot until endpoint by hand in order to make safely holding knot.

4. Practice

Sutures and suture materials, suture removal

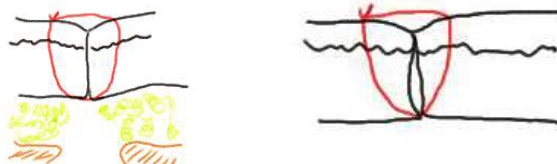
Aspects of wound closure:

- Stitches should be placed about one cm from the wound edge in both side (usually stitches should be made toward us). Try to avoid suture materials to cut through tissues by placing them to close to the wound edge.
- Stitches should be placed the same distance from each other (c.a. 1 cm)
- Keep all knots on one side of wound.
- Stitches should take the identical part of the opposite side of the wound to avoid wrinkles and gaps.
- Avoid inverted wound edge (inverted wound edge will heal with thick scar)
- Stitches should be took the wound base in deep wounds to avoid dead spaces, where blood, seroma can accumulate.
- Avoid tissue ischemia by making the stitch to tight.
- Deep wounds should be closed more than one layer.

Exercise: make simple interrupted stitches with French needle and linen thread on skill model. Insert the thread into the French needle as we learned in practice 2. Elevate the far side of the wound edge with surgical forceps and stitch in the skin approx. 1 cm away from the wound edge. Softly grab the needle coming out in the middle of the wound and pull out. Avoid to harm the tip of the needle. Take the needle with hand and reinsert into the needle holder. Elevate the nearby wound edge and stitch from the middle of the wound and come out from the wound approx. 1 cm away from the wound edge. Stitches should be placed in one line and perpendicular to the wound. Pull out the needle from the skin with the needle holder and remove the thread from it. Take everything from our hands to the table. Make Wiener knots with alternate right and left hand. Place the knots away from the wound, foreign materials in the wound can disorder the wound healing. 3-4 knots should be enough. Pay attention to make the knots with a proper strength. If the knots are loose, they won't hold the wound edges together. If they are too tight, they will cause tissue ischemia and necrosis. After knotting, hold the two threads together and cut them off, leave a small piece of thread behind (approx. 1 cm). Making the second stitch we make the same procedure, but we make surgical knots with alternate right and left hand. 3-4 knots will also enough. The distance between two stitch should be 1 cm. Removing sutures: elevate the thread or the knot with surgical forceps and the cut the thread between the skin and the knot.

Bad suturing techniques:

Inverted wound edges Dead space in the wound



Unequal wound edges Knot in the wound



5. Practice

Practicing of basic sutures on porcine tissue (interrupted stitches)

1. Simple interrupted suture

We create a 5-6 cm long incision on the liver skin-specimen. We put the needle into the needle-holder. We grab the opposite side of the incision with a surgical forceps, and start sewing 1 cm far from the wound edge. Catch the top of the needle with the needle holder and pull the thread through until there is only 2-3 cm is left outside the wound. Take care of the needlepoint and the cutting edge. Grab the needle with hand and position it correctly again into the needle-holder. Grab the closer wound edge with the forceps and sew out from the incision in 1 cm distance from the wound edge. The suture should be perpendicular to the incision line. Put the forceps on the table. Grab the longer end of the thread with the left hand (on which the needle is). Go around the needle holder with the thread catch the shorter end of the thread with the needle holder end finish the first instrumental knot. Position the knot on one side of the incision; take care not to place it in the middle because it inhibits the wound healing. Make further 3 or 4 knots. The advantage of the instrumental knot, that there are just a few threads is waste if you leave only 2-3 cm out of the wound at the beginning. Do the same process on the following suture. The stitches should be 1 cm far from each other. Removing the suture: Hold the knot or one end of the thread with the forceps, and cut the thread just above the skin.

2. Vertical mattress stitch (so called Donáti-stitch, or vertical U-suture)

Fix the needle with the needle holder. Grab the opposite wound edge with the surgical forceps, and sew into the skin 1,5 cm far from the incision line. If the needle is hard to sting through, try to push from wrist. Catch the top of the needle with the needle holder and pull the thread through until there is only 2-3 cm is left outside the wound. Open the incision the view the wound base, and sew it too. Catch the top of the needle and pull it out from the wound. Take care of the needlepoint and the cutting edge. Grab the needle with hand and position it correctly again into the needle-holder. Grab the closer wound edge with the forceps and sew out from the incision in at least 1,5 cm distance from the wound edge. The next step is the so called backhand positioning of the needle. Grab again the closer wound edge, and sew into it 1-2 mm far from the edge. Catch the top of the needle with the needle holder, and pull it out. Fix the needle again into the needle holder, grab the opposite wound edge with the forceps and sew out from the wound the same, 1-2 mm from the edge. All the 4 points of the suture must be in one line, and perpendicular to the incision line. Get the needle out of the needle holder, and put the forceps on the table. Grab the longer end of the thread with the left hand (on which the needle is). Go around the needle holder with the thread catch the shorter end of the thread with the needle holder end finish the first instrumental knot. Position the knot on one side of the incision; take care not to place it in the middle because it inhibits the wound healing. Hold the two ends of the threads together and cut them together. Make further 3 or 4 knots. The advantage of the instrumental knot, that there are just a few threads is waste if you leave only 2-3 cm out of the wound at the beginning. Do the same process on the following suture. The stitches should be 1 cm far from each other. Removing the suture: Hold the knot or one end of the thread with the forceps, and cut the thread just above the skin.

3. Horizontal mattress stitch (horizontal U-suture)

Fix the needle with the needle holder. Grab the opposite wound edge with the surgical forceps, and sew into the skin 1 cm far from the incision line. If the needle is hard to sting through, try to push from wrist. Catch the top of the needle with the needle holder and pull the thread through until there is only 2-3 cm is left outside the wound. Open the incision the view the wound base, and sew it too. Catch the top of the needle and pull it out from the wound. Take care of the needlepoint and the cutting edge. Grab the needle with hand and position it correctly again into the needle-holder. Grab the closer wound edge with the forceps and sew out from the incision in at least 1 cm distance from the wound edge. The next step is the so called backhand positioning of the needle. Grab the closer wound edge with the forceps and start sewing 1 cm sidelong to the previous, and 1 cm far from the wound edge. Catch the top of the needle and pull it out, then fix it again backhand into the needle holder. Grab with the forceps the opposite wound edge, and sew out from the wound at least 1 cm far from the wound edge. The 4 stitches should form a *tetragon*. Get the needle out of the holder, and put the forceps on the table. Grab the longer end of the thread with the left hand (on which the needle is). Go around the needle holder with the thread catch the shorter end of the thread with the needle holder end finish the first instrumental knot. Position the knot on one side of the incision; take care not to place it in the middle because it inhibits the wound healing. Hold the two ends of the threads together and cut them together. Make further 3 or 4 knots. The advantage of the instrumental knot, that there are just a few threads is waste if you leave only 2-3 cm out of the wound at the beginning. Do the same process on the following suture. The stitches should be 1 cm far from each other.

Removing the suture: Hold the knot or one end of the thread with the forceps, and cut the thread just above the skin.

6. Practice

Practicing of basic sutures on porcine tissue (running stitches)

1. Simple running suture (with needle-thread combination)

We create a 5-6 cm long incision on the liver skin-specimen. We put the needle into the needle-holder. We grab the opposite side of the incision with a surgical forceps, and start sewing 1 cm far from the wound edge and without interruption finish the suture on the closer wound edge, exactly 1 cm far from the edge. Make an instrumental knot. Cut the shorter end of the thread with 1 cm waste. Continue sewing with the longer end where the needle is in a way, that all the stitches should be 1 cm far from each other. By the last stitch, do not pull the thread totally through, leave short loop, and tight the not with this double end. Make further instrumental knots. Hold the three ends together, and cut them 1 cm above the skin.

Removing the suture: Hold the knot or one end of the thread with the forceps, and cut the thread just above the skin, and pull the whole thread out.

2. Intracutaneous running suture

Create a 5-6 cm long incision, and fix the needle into the needle holder. Start sewing form outside the incision and get into the wound angle. Keep forwarding in the dermis layer. Get out from the incision by sewing the last stitch out from the wound angle. We make a knot to the thread itself, on both ends. We did correctly if the skin is bulk a bit, because the incision gets tensile free, and the scar will be very thin.

Removing the suture: Raise the end of the thread or the not, and cut the thread over the skin, under the knot, and pull the thread out from the other end.

9. Practice

Basics of the laparoscopic surgery: demonstration of laparoscopic surgical tools, training of eye-hand coordination

1. Veress needle is a double shaft needle with a spring-loaded obturator. It is designed for „blind” insertion with minimal risk of injury to underlying organs. The outer shaft has a sharp beveled needle end, whereas the inner blunt-tipped obturator protrudes beyond the sharp tip of the outer needle in the resting state. As the needle enters the peritoneal cavity, the loss in tissue resistance allows the spring mechanism to extrude the obturator back to its original position to prevent injury. Both reusable and disposable needles are available.
2. Small incision 1 cm long is made intra/subumbilically. The Veress needle is checked for proper function before use. With lifting the lower anterior abdominal wall by the left hand, introduce the Veress needle. The surgeon will be able to feel the needle piercing through the fascia and the peritoneum separately. The position of the needle is checked with a syringe containing saline: 1. aspiration should yield no bowel contents, bile, blood, or gas, 2. injection of 5-10 ml of saline should meet no resistance, and 3. repeat aspiration should not withdraw the injected saline because this would have dispersed in the peritoneal cavity. The needle is then connected to an insufflator and carbon dioxide is instilled at a pressure of 10 mmHg and with a rate of near to 1 liter/min. After adequate insufflation (tympanic resonance), the Veress needle is removed and the pneumoperitoneum is ready for operation.
3. Trocar ports are then used to insert first, the video-endoscope and then, the operating instruments into the peritoneal cavity. A variety of reusable and disposable trocar ports are available in sizes ranging from 5-mm to 25-mm. The commonly used sizes are: 5-, 10-, and 12-mm. They have two main parts: inner spit and outer cannula (port). First, a 5-mm disposable trocar port is presented. It has a safety shield mechanism that reduces injury to organs during insertion: it has a built-in safety shield that retracts to expose the sharp tip during insertion, and spring back on entry into the peritoneal cavity. After insertion of trocar ports the inner part (i.e. trocar or spit) is removed while, the outer part (i.e. port) stays inside the abdominal cavity. Trocar ports have a valve which allows introduction and withdrawal of instruments with minimal air leak.
4. A reusable 5- mm trocar port without safety shield is presented.
5. An 11-mm trocar port with a safety shield is presented. Correct holding of the trocar port during insertion.
6. A 10-mm trocar port without safety shield is presented. The spit is not sharp, it is cone-shaped.
7. A reusable 12-mm trocar port with safety shield is presented.
8. “5-11-mm trocar ports”: means that instruments with 5-11 mm in diameter are inserted without a need for reducers. In case of other trocar ports, when using 5-mm instruments through their larger-sized ports, reducers are required to prevent air leak.
9. A 15-mm trocar port without safety shield is presented.

10. A 10-mm in diameter trocar without safety shield is presented. After insertion of the trocar port the outer cannula (port) is screwed into the abdominal wall the same as a corkscrew.

11. First trocar port is inserted blindly. This is a 10-mm trocar port with safety shield. It is checked for proper function before use. After insertion of the trocar port the inner part is removed and, while the outer part remains inside the abdominal cavity. The port is then connected to an insufflator to supply the missing gas. Camera and light (fiber-optic) cable are connected to the optic (e.g. lens system). Then, the optic is inserted through the port into the abdominal cavity for inspection. The insertion of the subsequent trocar ports must be done under direct endoscopic vision.

12. Laparoscopic instruments are precisely ended long surgical tools with insulated or non-insulated handle. In most cases, these handles are ring-ended to guarantee a good grip. Close to our index finger a rotatable part is located for turning round the precise end. Some instruments have ratchet handle. First, a dissector is presented with a pistol handle.

13. Laparoscopic scissors with insulated handle. Above the handle there is a metal part, which is connectable to the electrocautery device. In this way, it will have both cutting and coagulating functions.

14. Curved dissectors are useful for preparation and gripping of fine tissues.

15. During laparoscopic operations two needle holders are necessary. One of this is shorter and thicker, namely “parrot”. The another one is longer and thinner, namely “flamingo”. Needle holders have linear (coaxial) handle.

16. Laparoscopic scissors.

17. Blunt-ended gripping instrument.

18. A crooked-ended instrument (Hook) is presented. Above the handle there is a metal part, which is connectable to the electrocautery device.

19. Dissecting forcepses (or dissectors) are useful for preparation and coagulation.

20. Laparoscopic irrigation/suction device. If its key is in the middle position the tool is closed. If we put it in forward position the fluid (saline solution) will irrigate the region (irrigating function), while setting it in a backward position leads to aspiration of fluids (i.e. blood, bile, etc.) (aspirating function).

21. Fan-retractor is useful to retract the liver during operation.

22. Dissector is demonstrated.

23-24. A disposable 10-mm in diameter 0° optic is presented. That one which has a bigger diameter and a white end is the ocular. Light cable is connected to the sideward metal part. The other end is the objective, which is going into the abdominal cavity. This rigid tool utilises the Hopkins rod-lens system to obtain clarity. End-viewing or 0° lens is adequate for most laparoscopic works.

25. A reusable 10-mm in diameter 30° optic is demonstrated. This side-viewing optic allows better visualisation of awkward corners.
26. Camera. The first generation endoscopic cameras are the one-chip cameras, whereas the new generations are the three-chip cameras. These latter ones produce images of a higher quality and a better colour.
27. Light cable. A halogen cold-light source provides illumination via a fibreoptic cable, and a videoscope (camera) transfers the eyepiece image to a high resolution video monitor.
28. In the videoptic system the the light cable and the camera join to the optic.
29. Endoloops are useful to ligate tissues during operations (Endoloop[®], Roeder-loop[®]). During laparoscopic suturing the atraumatic ski-shaped needle is used.
30. Monitor.
31. The insufflator tube is joined to the Veress needle.
32. Insufflator set. A filter is between the tube and the insufflator device, which is supporting the sterile CO₂ gas flowing into the patient's body cavity. With this device we can also monitor the most important parameters, such as intraabdominal pressure (here, 6 mmHg), the rate of gas flow (here, 5 liter/min) and the volume of the gas in the peritoneal cavity (here, 00.0 liter). Among these parameters, we can change the values of intraabdominal pressure and the flow rate.
33. The upper device is the camera set. The lower one is the light source with the light cable. The camera set is also joined to the monitor.
34. Here are the optic with the camera and the light cable, and they are joined to the camera set and the light source.
35. Electrocautery set.
36. Hook is attached to the electrocautery set.
37. Working of the electrocautery set by pedal. Cutting function is fulfilled by pressing the yellow pedal, while the coagulating function is excuted by the blue one.
38. To work with the monopolar electrocautery system the negative electrode should touch the patient's dry skin.
39. The irrigator is jouined to the device with plastic tubes.
40. Pelvitainer or trainer box. This is a laterally opened box. On the top of the box there are some holes to lead the laparoscopic instruments and the optic. It is a necessary thing in training the laparoscopic technique.
41. We cover the top of the pelvitainer with a paper (or cloth) sheet. The instruments are inserted through the ports and we can follow our activity only on the monitor.

Training of eye-hand coordination: one student is working, and the another one is holding the optic.

1. Task: red, green, and blue slips of the paper are grasped one-by-one and based on their colours are put in the Petri dishes. This is done first with right and then with left hands (for the left-handed students, in a reversed manner).

2. Task: needle insertion into the plastic case. We grasp the needle and the case with the instruments. Following this, the needle is inserted into the case. It will not be successful if the needle and the case are not parallel to each other.

10. Practice

Laparoscopic training in trainer box

Task: based on numbers and first with your right hand, put the rubber bands on the sticks located at the left side. Then, put these bands back to their original place with your left hand. The students are holding the optic by themselves. The duration of this activity is measured. A skilled student can perform this task in less than 2 minutes.

9. Practice

Microsurgery: basic instrumentation and adjustment of microscope, microsurgical stich insertion

Aim of the practice: to learn and practice the appropriate usage of basic microsurgical instruments, the suture-tying under magnification with a help of silicone rubber practice pad.

1. Appropriate handling of microsurgical instruments: to hold the following instruments as a pen. Instruments: curved-tipped forceps, jeweler (Adson) forceps, microsurgical scissors, microsurgical needle holder, strait dissector with locking system, vessel clip, microsurgical clip applicator, approximator

2. Loupe is a glasses like magnifying instrument. The eyepieces of loupe are adjustable to the surgeon's pupil diameter, but the magnification is fixed. Put on the instrument and adjust to our own pupil diameter, then fix the position.

3. Training in a laboratory with an operating microscope often takes long hours of concentrated work. This task is impossible to accomplish unless the surgeon has a comfortable and perfectly balanced position.

One should remove every object from the way of the legs on the ground which can disturb convenience. It is also important to have enough place for the knees, hence sitting at a table with drawers is not always suitable.

It determines two very important issues. On one hand, it affects the ability of manipulation, on the other hand it affects how we see through the microscope. We can only work without hand tremor if both forearms are resting on the table. One should not achieve this immobility by leaning on the elbows, as it quickly leads to fatigue and tremor of the hands. Turn the light source on, focus on the field and instruments held in both hands into the middle of the field trying different magnifications. The final adjustment is provided by the conformity of body position and microscope adjustments. After a few occasions, we just briefly and routinely perform these procedures.

4. Switch on the microscope. Position the eyepieces at 0 diopter. Adjust the fine focus. Set the interpupillary distance. Choose the lowest magnification and focus on the spot that you previously marked by using the coarse focus. Choose the highest magnification and adjust the fine focus also for this magnification. The reason for starting the fine focusing at the highest magnification is that the microscope will be focused in the smallest depth of the field, thus allowing a perfect focus at all magnifications. Switch to the lowest magnification without modifying the focus, and set the eyepieces to the lowest possible diopter. Adjust the diopters separately for each eye by rotating the lens of the eyepiece clockwise.

5. It is particularly important to practice the stitching and knotting in microsurgery. We use 10/0-7/0 atraumatic needles which are permanently attached to a fine monofilament thread. The cross section of the needle is somewhat flat so it cannot turn around along its axis when held in the needle holder. We grab the needle closed to the thread (at 1/3 of the needle). At the beginning even grabbing of the needle represents a problem.

The recommended technique is shown here. Holding the thread in the left hand, lay the greater curvature of needle on the surface a way it gets into position where it is suitable to grab it with an instrument held in the right hand.

For a right-handed person the steps are as follows: the needle is held in the forceps in the right hand, the forceps in the left hand is put under the incision (to expose the wound on the right side). Never grab the edge of the structure to be sutured with the forceps. The axis of the needle should be held perpendicularly to the surface to be sutured. The distance from the edge should be approx. two times the diameter of the needle.

On the left side: Let us make the tip of the needle get out exactly in line with the stitch on the right side. When the tip of the needle is visible on the left side, we grab it with the left forceps and pull the needle out. Be careful and do not disconnect the thread from the needle. Let us try to avoid surface friction by retracting with the left forceps when the needle is pulled through the rubber. When we pull the thread through counteract the friction by retracting with a forcep held in the right hand.

6. Microsurgical knotting evolves the simultaneous use of two instruments, similarly to the laparoscopic approach. In the clinical practice, two major methods of tying knots are applied: the one-handed and the two-handed versions. The one-handed version resembles the method used in macroscopic instrument-aided knotting procedures, because the long part of the thread is held always in the same hand, whereby the thread is passed into the other hand during the two-handed procedure.

Grab the long thread with the right needle holder at a distance which can be easily looped around the tip of the left forceps (direction: towards the “short end”, distance: 3 times the length of the “short end”). Reach and pull the “short end” through the loop with the left forceps (*meanwhile do not let the loop slip off*). Pull only the “long end” while firmly holding the “short end”, and tighten the knot.

When the knot is tightened, the edges of the rubber should only touch each other - do not overlap! In order to achieve this, the distance of the stitch from the edge should not be large and the knot must not be very much tightened. Do not pull the “short end”, pull only the “long end” otherwise the knot loses its ideal structure.

Move the “long thread” to the side of the short end, grab the “long end” now with the left hand (distance: 3 times the length of the “short end”) and wrap it around the right forceps (direction: opposite to the “short end”) then grab the “short end” with the right forceps and pull it through the loop, and tighten the knot. Eventually, cut both the “short and long” ends approx. 3 mm long.

10. Practice

Microsurgery: insertion stiches

The matter of the previous lesson is repeated during this section.

1. Taking on the appropriate body and hand position. Adjustment of the microscope or loupe.
2. Practice of the grabbing and adjustment of the needle–thread complex under magnification.
3. Making a 2 cm long incision on the rubber pad.
4. Insertion of interrupted microsurgical stiches. The distance between stiches are 0,5-1 mm.
5. Knotting under magnification.
6. A repeat the above mentioned excersises 5 or 10 times on the incisions lay in different directions.

The trainee should be able to tie 6 knots in 10 minutes to consider himself proficient in this excersise.

10. References

- Heinz Schott. A medicina krónikája. Officina Nova. Budapest, 1993.
- Jürgen Thorwald. A sebészek évszázada. Gondolat. Budapest, 1959.
- Roy Porter. Vér és virtus. Az orvostudomány rövid története. HVG. Budapest, 2003.
- Gaál Csaba. Sebészet. Medicina. Budapest, 1997.
- Kiss János. Gastroenterológiai sebészet. Medicina. Budapest, 2002.
- Lukács Géza, Szállási Árpád, Gazdag István. 100 éves a Magyar Sebész Társaság. Tonyo-Gráf. Budapest, 2006.
- Boros Mihály (szerk). Sebészeti műtéttan. Innovariant. Szeged, 2006.
- Gaál Csaba. Alapvető sebésztechnika. Medicina. Budapest, 2000.
- Szabó Zsolt. Sebészeti varróanyagok. Medicina. Budapest, 2004.
- Kiss János. L.C. Laparoscopos cholecystectomy. Meditor. Budapest, 1992.
- Mack P, Ooi LL. Manual of basic operative laparoscopic and thoracoscopic surgery. Forces Publication, Singapore, 1993.
- R.T.H Ng. Microsurgery Training & Graded Exercises. In: Peter Mack (ed): Clinician's Guide to Experimental Surgery. Image Medicus, Singapore pp 155-188, 1994.
- Boros M, Szabó A (szerk). Nagyított Sebészet. Tiszapress, Szeged pp 78-84, 2006.
- J.S.P. Lumley. Microsurgery: renewed sensation. Journal of the Royal Society of Medicine 1981; 74: 715-718.
- J.H. Jacobson, E.L. Suarez. Microvascular Surgery. Chest 1962; 41: 220-224.